

## Interview with...

Dr. Hans-Willi Herrmann

**The motto of your dental practice is: “We save teeth”. Where, for you, must the limits to this policy of “saving teeth” be set? Or to put it differently: does this motto of yours mean that you will save any tooth, at any price?**

The way you put your question implies that saving teeth at any price must be wrong, so obviously, I’m best advised to agree and say: yes, also in matters of tooth-conservation there is a limit that has to be considered, and beyond which the utility gained is outweighed by the costs required to gain it. But the saving of teeth, carried out consistently, is process that gives value for money whatever the cost. It’s worth the price paid for it firstly in the sense that the fees charged for tooth-conserving dental services are low compared to those charged for implantological services or dental prosthetics, in view of the amount of time that needs to be expended respectively on these different sorts of treatment. And even more “worth its cost” in the wider sense that tooth-conservation means avoiding the high subsequent costs and the other drawbacks that attach by their very nature to implantological and dental-prosthetic procedures.

On the level both of diagnosis and of treatment, the essential thing is to distinguish between how far a tooth can be conserved and how far it is worth conserving it. The first question is a question of making full use of all that is medically possible at the present point in time. The second question is a question of the necessarily limited financial resources actually available in terms of costs that will really be covered by state or private health insurance institutions, and therefore of the financial circumstances and the will and wish of the patients concerned, as compared to the available alternatives which may possibly offer a better outlook. The decision regarding whether a tooth can be conserved is ultimately a decision for the dentist providing the treatment. The decision as to whether it is worth conserving, however, is ultimately a decision for the patient.

**How do you proceed in order to establish whether a tooth is able to be conserved and worth conserving? What role is played in such a procedure by X-ray technology and cone beam computed tomography (CBCT)?**

It goes without saying that endodontics – which, as the name implies, is concerned with the interior of the tooth – needs X-ray images. And this not only

for its diagnoses but also for the actual carrying-out of endodontic work, and for the monitoring of its progress.

One can often establish the degree of conservability of a tooth simply from the basic clinical parameters, such as its periodontal situation and degree of looseness, and from the condition of the remaining tooth substance. Also from conventional X-ray images. There are, however, a whole series of potential findings which remain beyond the scope of traditional 2D X-ray diagnosis. We all know – and we knew even before Seltzer and Bender’s legendary 1961 article *Roentgenographic and Direct Observation of Experimental Lesions in Bone* – about the weaknesses and limitations of conventional two-dimensional X-ray technology. Physicists draw attention to the Beer-Lambert Law. I would rather express the problem in more graphic terms as one inhering in the fact that we are dealing here with a two-dimensional representation of a three-dimensional state – something that necessarily involves a certain loss of informational content, just as a shadow contains less perceptual “information” than the object which casts it.

As an example here I could cite the way that the complete loss of bone structure in the area of the maxillary sinus floor which one can almost always assume to be present where extended periapical lucencies appear around the maxillary molars will nonetheless not come to light on normal dental X-ray film or on panoramic radiographs. Such conventional methods will also tend to be unable to prove the presence, or map the course, of additional root canal structures – i.e. be unable to demonstrate, for example, the existence, or otherwise, of the notorious “fourth root canals” in maxillary molars, or of “second root canals” in mandibular front teeth and mandibular premolars and in the distal roots of mandibular molars.

**What type of endodontic questions do you use cone beam computed tomography to solve?**

I use it to examine and test whether certain teeth are indeed capable of being conserved, to clear up certain anatomical questions, in traumatological cases, and for the verification of discrete apical lucencies which lie beyond the effective scope of conventional X-ray diagnosis.

**What advantages does three-dimensional imaging offer in endodontics, as compared to conventional X-ray technology (I mean in dialogue with the patient, during diagnosis, for the planning of the treatment, and for monitoring and check-up)?**

Well, I can sum up the advantages very briefly and succinctly. It provides us with clear facts, whereas previously, on the diagnostic level, we dentists were often just groping around in the dark.

**Where would you say, in your field of specialization, that CBCT imaging reached the limits of its capabilities?**

Well, firstly certain physics-related limits presently exist as regards the degree of image resolution that it is possible to achieve. In actual practice, though, there is also the problem that artifact may arise even in CBCT imaging due to the presence of radio-opaque structures. Such structures are to be found everywhere in the field of dentistry, be it in the form of fillings, fixed restoration, and metallic or ceramic root pins.

**Since when have you been using cone beam computed tomography? How long have you owned a Morita CBCT system? What sort of device, in what sort of design, do you use? And what was it exactly that prompted you to make the purchasing and investment decision to buy just that design/model?**

Since February 2012 we've been working in our surgery with Morita's Veraviewepocs 3D F40. The particular criterion which prompted my decision to buy this specific model was the image quality. There are only very few devices on the market at the moment that are capable of delivering results in this respect that satisfy endodontic purposes. The F40 is the smallest device in Morita's "family" of 3D X-ray devices, which also comprises the R100 and the 3D Accuitomo 170. The field of view provided by the F40 – measuring 4\*4 cm or 8\*4 cm – has proven to be perfectly adequate for the investigations we want to carry out and displays a greater sharpness of detail, combined with less exposure to radiation for the patient, than is the case with the results produced by larger fields of view.

Two other very important factors for me were the reliability of the product and the support provided by the company. Our Root ZX unit, with which we have been working uninterruptedly since 1993, has never let us down. I only wish I could say the same of all the equipment we have in our surgery. Also with regard to other Morita products with which I've come into contact in the course of the years my experience has always been a positive one. Particularly in view of the horrifying accounts that I had heard from colleagues regarding the kind of after-sales service and support that is provided, in the case of equipment breakdown, by certain other companies in the field of radiology, it was very important to me, given the amount of invested money at issue here, to know that, behind the product, there stood a corporate philosophy that set a high value on maintaining good long-term relations with the customer.

Another feature of the Veraviewepocs 3D F40 that the greater part of dental surgeries surely find indispensable is the fact that it is a combination unit which can also be used for ordinary panoramic X-rays. This is all the more appealing given the modest difference in price between this combination unit capable of both CBCT and panoramic imaging and more conventional units that provided panoramic imaging alone. Since our day-to-day work is focused on endodontics, which requires extremely high-resolution detailed images of the sort produced by dental film, the number of panoramic X-rays carried out at our dental surgery was always far below the average. For long periods, we carried out none at all.

For us, then, a panoramic-imaging X-ray apparatus was at best a “nice to have” item, at worst something we didn’t need at all, so if there had been a suitably reasonably-priced stand-alone CBCT unit on the market at the time we were shopping for new equipment, we’d probably have gone for that. Today, though, I’m glad that we opted for a unit that included a panoramic-imaging function, because the Morita CBCT unit also offers, with the so-called “Scout OPG”, a target-area adjustment of the CBCT field that is both easy to operate and very reliable and that we would not want, now, to try to get by without. I can only advise anyone who is in the market for equipment of this sort to take care to ensure, when they are making their purchase choice, that the unit they buy comprises this extremely helpful feature.

**When you decide to use the CBCT unit, how do you inform the patients about this, and what kind of reaction do you get from them?**

Well, usually in my initial interview with the patient we discuss the findings that emerge from the conventional 2D X-ray images. This means that the need for an additional 3D imaging tends to become clear to the patient directly and naturally just as a result of their recognizing the inadequacies, in certain respects, of the 2D imaging technique. Often it is the patient him- or herself who presses for the use of 3D imaging, seeing as he or she does that the 2D images are not enough, and asking questions about them.

As regards feedback when I suggest the possibility of a 3D-based diagnosis, reactions can range across the whole spectrum of possible responses. Some patients are spontaneously very enthusiastic about all the additional information that CBCT can provide (as one patient put it: ‘Now that this device is available, how can one possibly do dentistry without it?’). Others reject the possibility just as firmly, due to the higher costs involved, or the greater exposure to radiation that follows necessarily from the nature of the process.

**With regard to one of these last concerns you mention, could you say a few words about just how 3D diagnoses are actually billed for? How are the CBCT images charged to patients with statutory health insurance, and how are they charged to those who are privately insured? (In the case of a private health insurance company’s bearing the costs, are 3D images comprised in an official Schedule of Fees for Dental Services?)**

The Schedule of Fees for Dental Services doesn’t specifically comprise an entry for CBCT. But the Schedule of Fees for Medical Services is also open to dental practitioners, and this latter includes, as Item 5370, “Creation of a 3D X-ray image” and, as Item 5377, “Analysis and appraisal of 3D images”.

**How intensively, or how long, did you need to study the working of the unit before you were able to use it properly in your day-to-day surgery work? How much time did you have to spend, for example, on radiation-protection training for yourself and your staff?**

The time we had to spend on that really wasn't excessive. It goes without saying that any new technology necessarily requires introductory training sessions. And I certainly remember the sessions for the Morita unit as being much more interesting and entertaining experiences than the obligatory periodical "refresher" training sessions in radiological matters that are offered by the German Dentists Association. If a person requires such further training, then, they should definitely consider opting, as an alternative, for the one leading to the specialized test in CBCT techniques, since this training really does provide additional, practically useful skills and knowledge.

**Do you use the device exclusively for patients permanently under your own care, or does your surgery also take referrals? Is the device used to full capacity in your dental practice? Is it employed frequently enough to "pay its way"? Can you say something about the time it takes, roughly, to recoup one's initial outlay on such a product?**

As far as the time needed to recoup the money one initially invests by acquiring a CBCT unit, I'm sure that sample calculations bearing on that question have been drawn up by the manufacturers and traders of such devices, and that colleagues who are potential buyers can get hold of copies of these if they wish to.

However – although I certainly won't contest that investments in surgery equipment have to make proper financial sense – I must add that I am no great believer in the paramount importance of such sample calculations. Circumstances and conditions in each individual surgery tend to be too different to those existing in other surgeries for such calculations to constitute more than a very approximate and really, in the end, quite arbitrary indication. If a colleague really wishes to form an idea, then, of how economically viable it is to run a CBCT unit specifically in his or her own dental surgery, my recommendation would be that they set about systematically posing to the individual patients who form their surgery's clientele the question of how much sense each patient feels CBCT procedures would make for them. This should be done over a representative period of time and strictly within that group of patients whose medical indications suggests CBCT might be relevant to their needs. In this way, one would arrive at some key figures which might provide a reliable basis for model calculations more realistic than the sample calculations I referred to just now, because specific to the dental surgery considering the purchase.

As to the question of own patients and referrals: I bought the device for the patients of our surgery. I am of the view – and, here too, it could be that I stand at odds with the model calculations drawn up by manufacturers and suppliers – that one should be aiming to recoup one's initial investment in a product like this already within the scope of the business of one's own surgery. If your plan is to recover the money you've laid out on a CBCT unit only with the help of the referrals it will gain you, then you'd have done better not to buy one in the first place. As more and more local surgeries acquire such pieces of equipment, this

referral clientele will gradually become noticeably less significant in number. It's better, then, to take into account, when calculating the long-term economic viability of operating such a unit, just the immediate clientele of one's own surgery. And if it brings in referrals too, well, all the better. As to the amount of time we have for the unit to recoup its costs: the panoramic-imaging unit we had before was in service for 18 years. I think I would be fooling myself if I reckoned with a service life of such a length for a unit belonging to the CBCT sector, given how rapidly technology is developing in this field. For my own part, my assumption was that the unit would have a period of use of 8 years as a "state of the art" application. If one doesn't set such high standards, of course, as regards keeping fully abreast of technological developments, then one can reckon with longer service lives and periods of use – which naturally makes, in turn, any such unit into a product providing better value for money.

**Where X-ray technology, and above all CBCT technology, is used, there often also applies a legal requirement that some clear medical indication justifying its use be present. What is the current state of affairs in the area of endodontics as regards this justifying medical indication? Do the German Association for Endodontics and Traumatology (DGET) and the German Society of Dental and Oral Medicine (DGZMK) have different understandings of how to proceed here? What sort of latitude for individual professional judgment do you enjoy when deciding whether to proceed to a CBCT imaging?**

The decision as to the necessity, or otherwise, of carrying out each individual X-ray imaging – that is, the decision as to whether or not a justifying medical indication is present in each particular case – is a decision which is always taken by the dentist performing the treatment. Guidelines serve an ancillary, orienting function but can lay no claim to comprehensiveness. New guidelines are shortly to be published and I don't want to anticipate them here. But as much to be welcomed as these new guidelines may be, inasmuch as they provide broader and more detailed indications for the endodontic field per se, the dilemma remains that not even this attempt to adjust and adapt current guidelines can really do sufficient justice to the extremely rapid developments currently taking place in the field of 3D X-ray diagnosis as regards both diagnosis itself and the monitoring of the course of treatment – not when one considers the length of time that was necessary in order to draw up such a series of scientific recommendations, which represent an interdisciplinary consensus between all the constituent sub-disciplines within dentistry. The number of justifying medical indications in the endodontic field is, after all, really significantly larger than the average of those reflected in sets of guidelines. A set of guidelines – even where we are dealing, as in the present case, with guidelines existing in a very recently updated form – is always to be considered as a mere approach to the problem oriented rather retrospectively, toward past states of affairs, and as one, moreover, which is not characterized by medical concerns alone but also by

the specific concerns and interests of certain “guilds” and which must, necessarily, lag behind what is actually currently medically feasible.

It is all the more to be regretted that it is currently common practice for private health insurance companies in Germany to refuse to refund to those insured by them the costs of any measures connected with cone beam computed tomography and even, by denying wholesale the necessity for such measures and by suggesting that they fail to observe the ALARA principle, to bring the dentists performing such treatments into discredit. This kind of thing can often happen without the images that have already been made available even being submitted to the judgment of a qualified expert. Here, I can only advise the colleagues who have had to suffer this sort of thing to not let themselves be intimidated by such rejections and disparagements, which are clearly motivated by financial considerations, and to steadfastly continue to seek dialogue with the insuring bodies concerned.

**Can you give an example of an instance where conventional X-ray diagnoses failed to provide a basis for any clear statement about a case and you then carried out CBCT imaging which produced a clear result?**

I suppose the occasion on which I really first realized clearly what the CBCT unit could achieve was a case where, just shortly after we had begun using the CBCT unit in our surgery, a 38-year-old female patient was referred to us, complaining of toothache of indeterminable origin.

Root canal treatment had already been carried out by the patient’s own dentist on tooth no. 45, and had been reworked, due to continuing pain in the tooth, but without success. It was suspected that the tooth might contain a second root canal, but it had proven impossible to firmly demonstrate, by clinical or by conventional radiographic means, the existence of such a canal. The manner of proceeding that the patient’s own dentist had considered was the reworking of an inadequate root canal filling in the adjacent tooth no. 46, indicated to be faulty by certain apical lucencies – a task which he was also considering referring to our surgery (see Fig. 1). The CBCT imaging, however (see Fig. 2) not only proved beyond doubt that there did indeed exist a second root canal in tooth no. 45 – namely, in a lingually adjacent root running separately from the main root – but also revealed, in this same tooth, an apical lucency in this same lingually adjacent root along with an interradicular lucency in the furcation region. Furthermore, the CBCT was able to show that, in order to lay open this hidden second canal and render it accessible to intervention, all that would be required would be drilling, at a certain point, to a depth of no more than 3 millimeters. Pain in the tooth ceased after the first treatment session and was definitively dealt with by carrying out a root canal filling of the second canal and by the fitting of the tooth with an adhesively anchored glass-fiber pin (see Fig. 3).

**What was, for you, the most surprising finding ever revealed by a CBCT imaging?**

Here, I'd like to give two cases as examples. In the first case, the revealing, by CBCT imaging, of the presence of a sialolithiasis in the excretory duct of the *glandula sublingualis* (see Fig. 4). A female patient aged 34 had been referred to us for the reworking of an already-existent root canal filling in tooth no. 46, because her own dentist had considered this filling to be responsible for a massive swelling in the right-hand edge of the mandibular area, which had manifested itself during pregnancy and had been treated with antibiotics at the time. I argued, when the case was referred to us, that we should provisionally leave the root canal filling as it was and proceed rather to the surgical removal of the sialolithiasis, since the symptoms described did not concord with the X-ray findings for tooth no. 46.

The other instance I'm thinking of is the case of a 62-year-old female patient who, after her own dentist had extracted tooth no. 45, was continuing to complain of toothache and requested the reworking of the *alio loco* root-canal-treated tooth no. 46 (see Fig. 5). CBCT imaging revealed, as the cause of the persisting pain, rather the existence, in tooth no. 47, of a sub-gingivally located, clinically undiagnosable external resorption which extended right into the vicinity of the pulp (see Fig. 6).

### **Can you imagine getting by without your CBCT unit now?**

I can no more imagine that than I can imagine getting by without my Root ZX apex locator, which I have been using since 1993, or my Zeiss dental microscope, which I've been using since 1998. I look upon the CBCT unit, along with the other pieces of equipment I've just mentioned – to which I would also add the new mechanical nickel-titanium instruments and MTA as a new type of material for fillings – as being absolute “game-changers” as regards endodontic treatment.

### **Is there a final piece of advice you would like to give your colleagues as regards these matters?**

I would advise colleagues to take a very close look, before making any purchase decision, at the kind of quality of image, in the sense of a “gold standard”, a piece of equipment like Morita's 3-D Accuitomo 170 can provide when used in high-resolution mode with a small field of view. Finally, I would, in their position, closely examine, so as to be able to make a comparison, images which have been produced, in the course of the real day-to-day work of their surgeries, by colleagues who are already using the pieces of equipment in question. In this way, the absolute quality, and the cost-benefit relations, as regards the various CBCT units counting among the narrow selection already made will very soon become clear.

The apparent saving in costs achieved by purchasing a unit on sale at a cheaper price will prove to be self-defeating if, right after the purchase is made, the hoped-for and promised high quality of image, which had appeared to be





guaranteed by the manufacturer's or dealer's sample images, proves not in fact to be delivered by the unit once it is installed in the surgery and used in its day-to-day work.

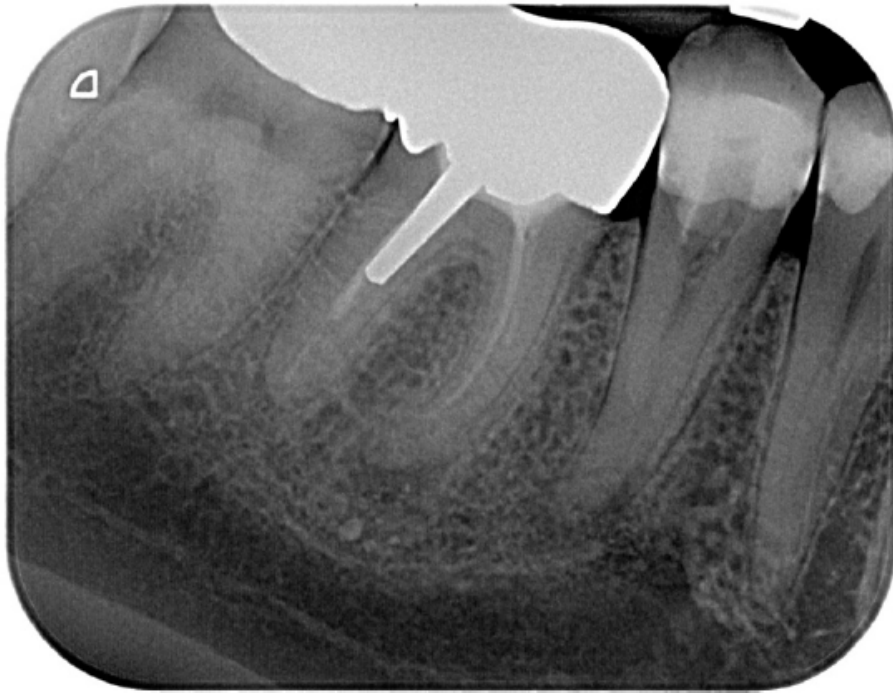

Fig. 1: Dental film of teeth nos. 45, 46 taken in response to unclear diffuse complaints of toothache in the area of the right-hand mandibular lateral teeth.

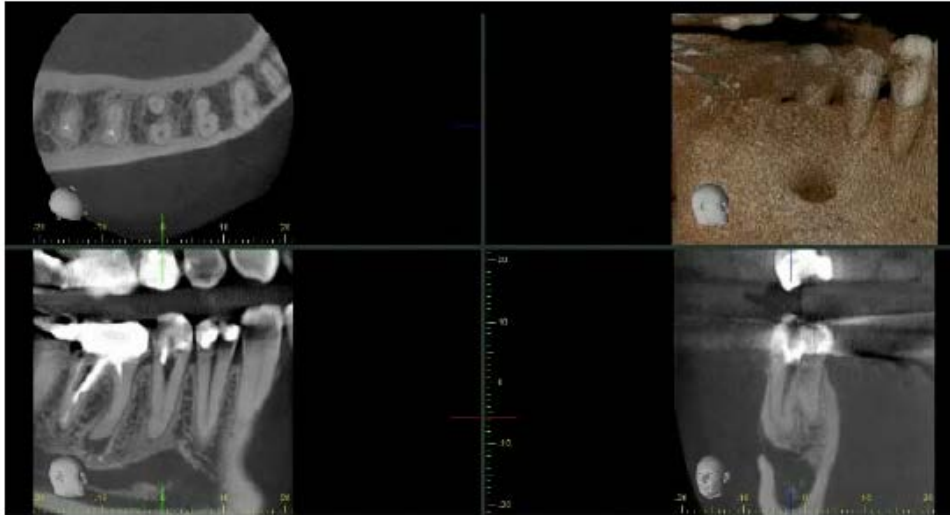

Fig. 2: The CBCT imaging reveals the existence of a second root canal in a lingually adjacent root running separately from the main root, along with an apical lucency in the same lingually-adjacent root, and an interradicular lucency in the fircation region.

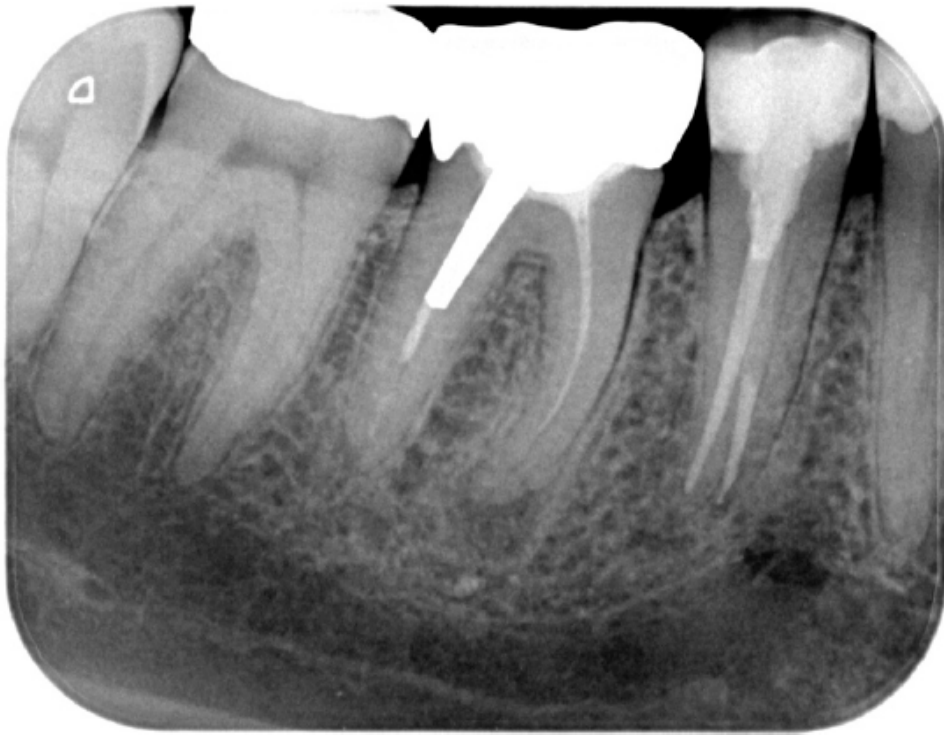

Fig. 3: Check-up X-ray image of tooth no. 45 after root canal filling and insertion of an adhesively-anchored glass-fiber pin.

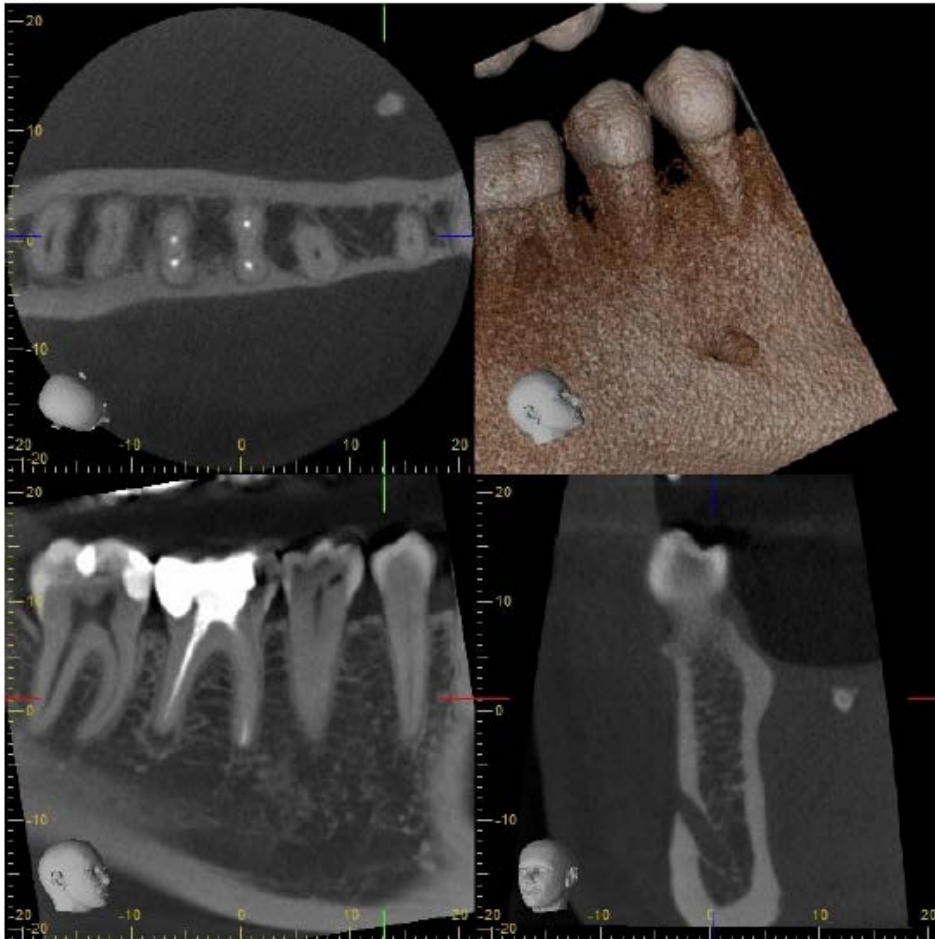


Fig. 4: A fortuitous finding emerging during pre-treatment X-ray diagnosis – a sialolithiasis in the excretory duct of the *glandula sublingualis* representing the probable cause of an earlier-experienced massive swelling in the soft-tissue area.

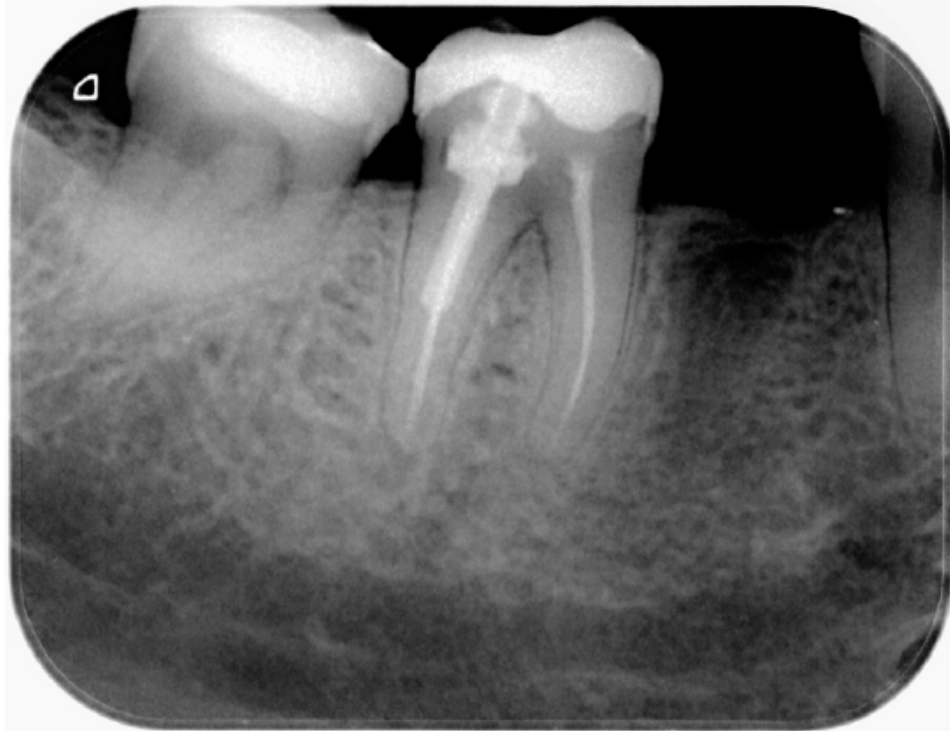


Fig. 6: Dental film of the region around teeth nos. 45-47 taken in order to clear up the causes of diffuse toothache in the area of the right-hand mandibular lateral teeth.

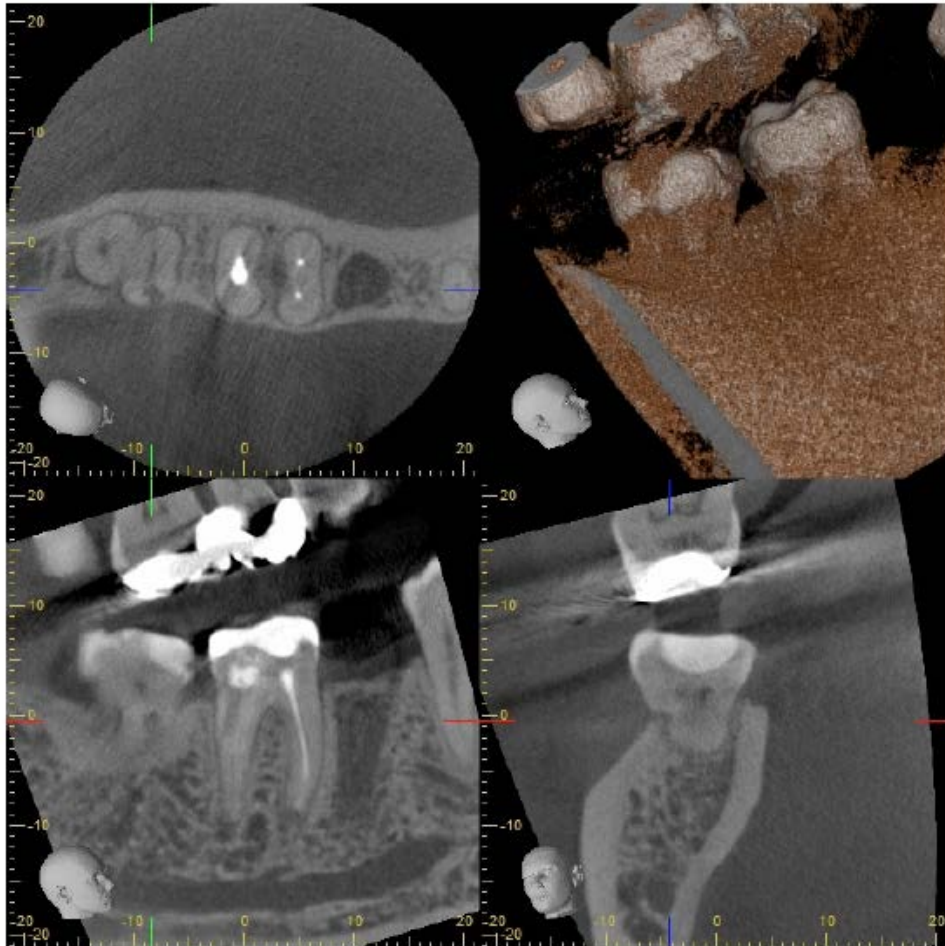


Fig. 7: The CBCT imaging reveals an external resorption in tooth no. 47 to be the cause of the pain.