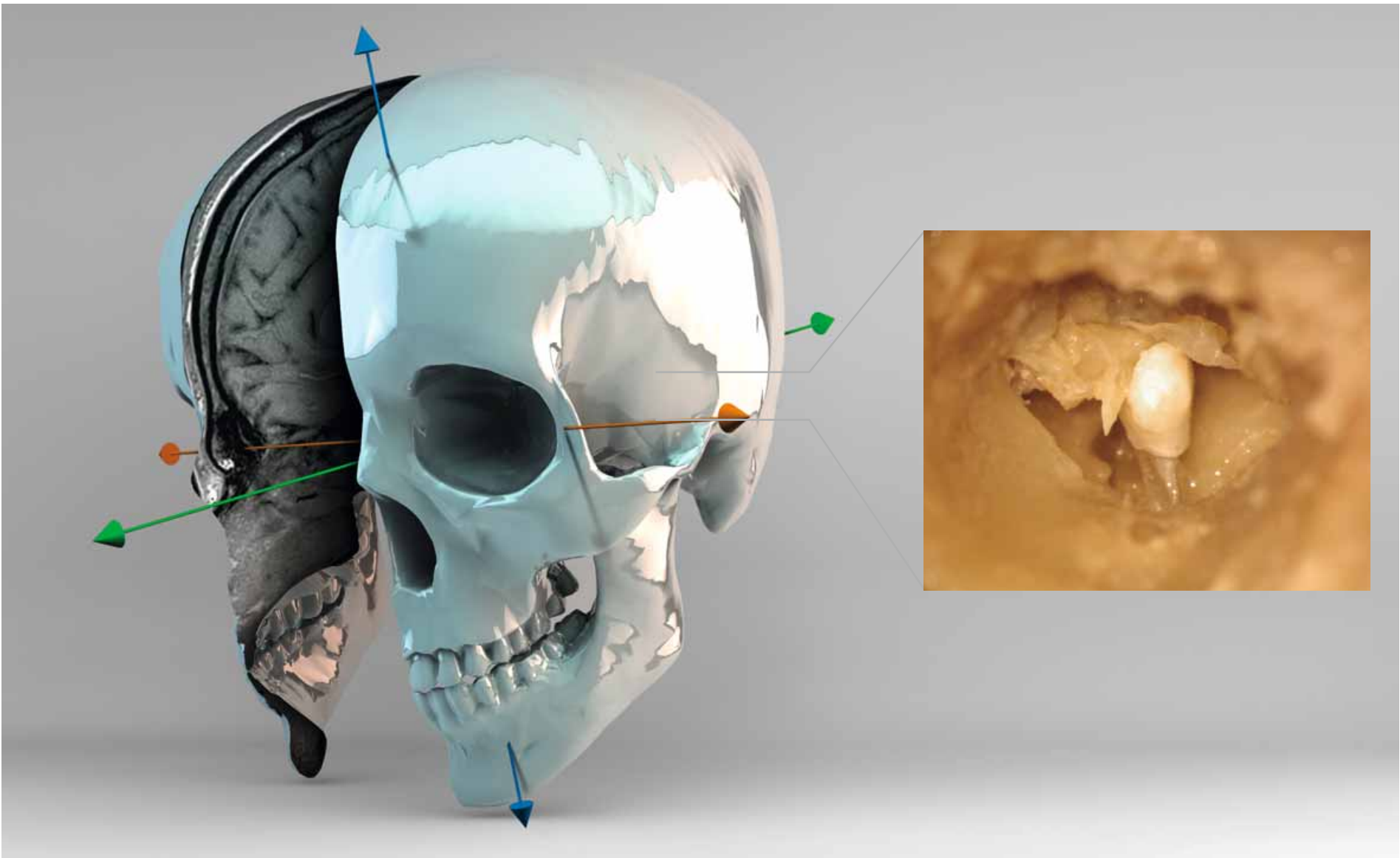

3D Accutomo Clinical Case Evidence

The Advantages of DVT for Ear-, Nose- & Throat-Diagnostic

Thinking ahead. Focused on life.





Dear Colleagues,

I am very happy to present you now some data on cone beam tomography (digital volume tomography) with this booklet. This imaging procedure is highly interesting in otorhinolaryngology and I am convinced that it will play a major role in future routine diagnosis. In order to summarize detailed knowledge on this procedure we decided to create this booklet. Special thanks to my co-worker Dr. Christian Güldner and of course also to Morita Company that finally made this booklet possible. Please inform yourself of the modern technique. It does not only on the achievements of the examiner but mainly on the theoretical background that each physician is supposed to have.

A handwritten signature in black ink, appearing to read 'J. Werner'.

Jochen A. Werner, MD
Professor and Chair
Dept. of Otolaryngology, Head & Neck Surgery
UKGM, Campus Marburg

Index of Contents

[04 - 05] **Introduction of 3D Accuitomo – Compact, High-Resolution, Low-Dose**

[06 - 09] Efficient Workflow Integration of DVT

[10 - 11] i-Dixel Image Processing Software

Temporal Bone Cases

[12 - 13] **Anatomy of the Temporal Bone in Digital Volume Tomography**

[14 - 15] Axial Plain, caudal

[16 - 17] Axial Plain, cranial

[18 - 19] Coronal Plain, from anterior to posterior

[20 - 21] Sagittal Plain, from lateral to medial

[22 - 23] Osteoma of temporal bone

Anterior Skull Base Cases

[24 - 25] **Anatomy of the Anterior Skull Base in Digital Volume Tomography**

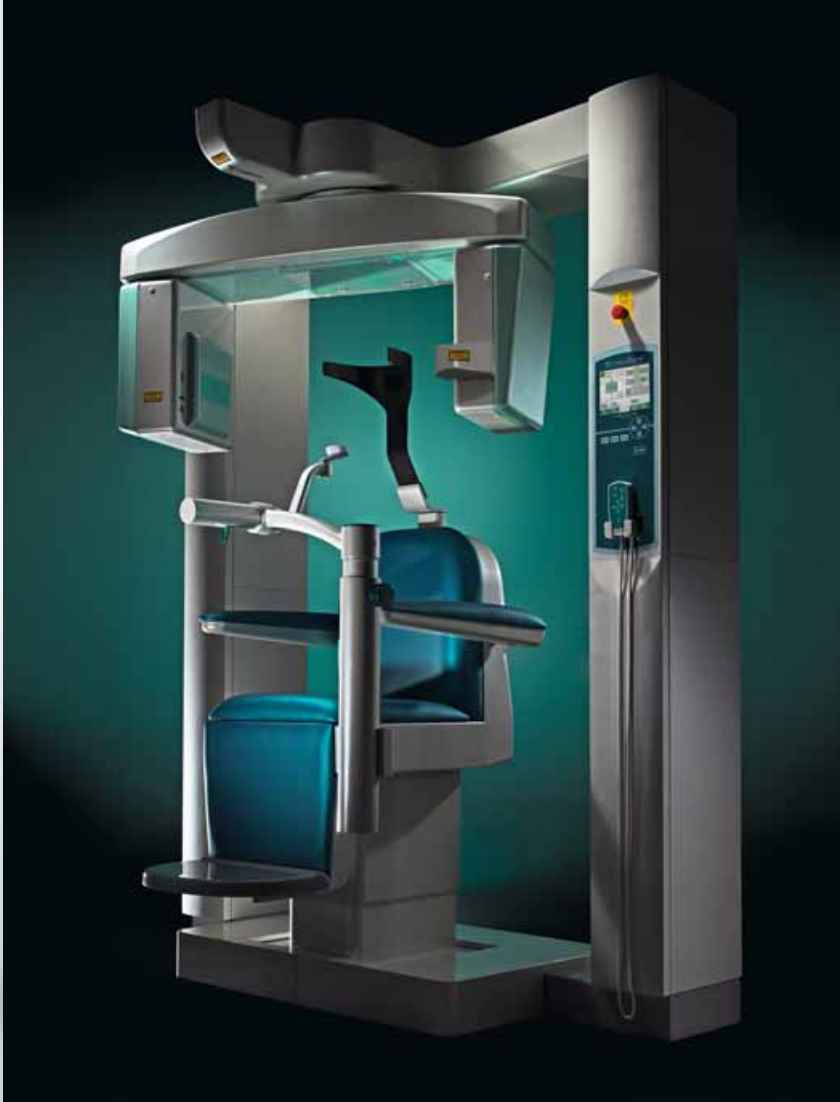[26 - 30] Coronal Plain, from anterior to posterior

[32 - 33] Axial Plain

[34 - 35] Sagittal Plain

[36 - 37] Nose and paranasal sinus

Introduction of 3D Accuitomo – Compact, High-Resolution, Low-Dose



Advantages of Cone Beam

3D Accuitomo 170 is a cone-beam CT or also called DVT; digital volume tomography, which is designed for imaging of head-and-neck regions, especially for temporal bone and sinuses. With one single rotation of the x-ray tube and area detector around the head of the patient, it provides high-resolution volumetric data of a small region, which is suitable for specialized medical applications of otorhinolaryngology and maxillofacial fields.

The patient is in sitting position during scan, instead of lying on the table. The patient chair moves up/down, left/right and back/forth to position the imaging area to the region of interest. X-ray tube assembly and two-dimensional x-ray area detector are mounted on each side of the arm, which rotates 360 degrees around the patient during scan. 512 projected x-ray images are generated during one rotation, which takes about 18 seconds in the standard scan mode. The projected images are reconstructed into a volume data by the filtered back-projection method. The volume data can be shown as tomographic images sliced from any desired angles, or as three dimensional volume rendering images.

This system is also designed to be space-efficient compared to existing CT systems in the market, it is even suitable for a small clinic. This type of device can be a far more practical and useful tool than an existing CT for special applications requiring detailed imaging of the fine bone structures of the middle ear, etc.

By using an area detector with very small pixels, it is possible to obtain high-resolution images, compared to a medical CT. Because of the two dimensional detector, the resolution of the sagittal and coronal slices is as high as the one of the axial slices. The volume data consists of small isometric cubes called voxels. The minimum selectable voxel size is 80 micrometers, which can depict very minute object. This is particularly useful in visualizing small bone structures such as temporal, maxilla or mandibular bones.

The imaging area size is selectable, depending on the applications. This is effective to reduce unnecessary x-ray exposures to the patient. The imaging area is cylindrical and the maximum size is 170 mm in diameter and 120 mm in height, which covers most of the major part of head-and-neck regions.

In this case, a large voxel size is used to create the volume data in order to reduce the data size and processing time. The minimum size is 40 mm in diameter and 40 mm in height, which is suitable for the middle ear or a couple of teeth. In this case, the minimum voxel is used to depict more precise structure of bony tissues. A middle sized imaging area with a middle sized voxel can be useful for sinus region, for example.

If a larger image includes a smaller region of interest in it, the zoom reconstruction function can create more precise image of the region from the original projection data by recalculating with a smaller voxel, without taking another scan.

Efficient Workflow Integration of DVT

Sharing Image Data

Installing i-Dixel software on all intra-clinic computers enables sharing of image data on each linked client computer. Observation of images on non-network computers can be achieved with the One Data Viewer, and the One Volume Viewer without installing i-Dixel.

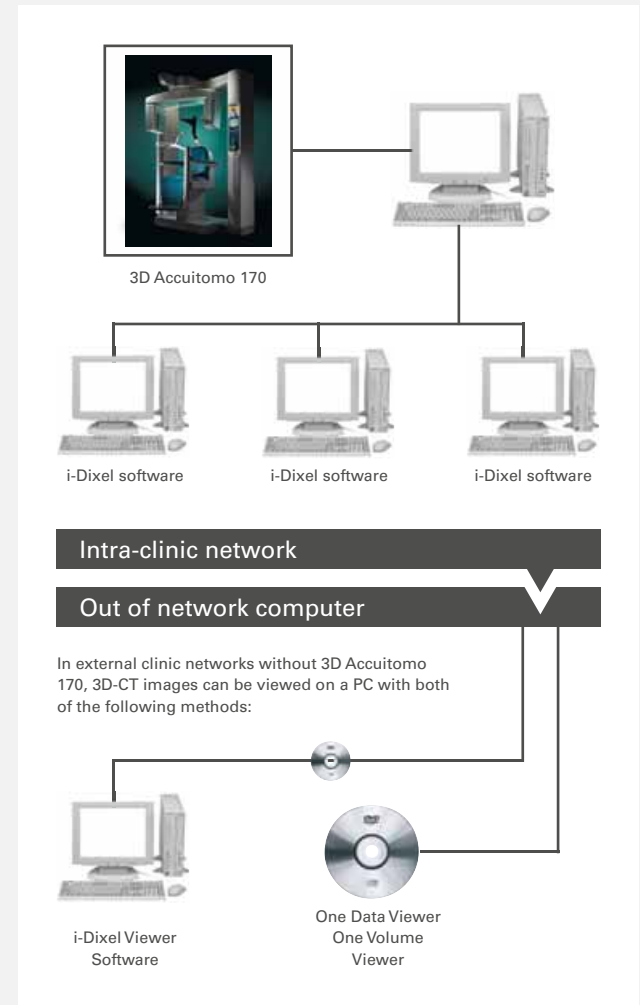
One Data Viewer & One Volume Viewer Software

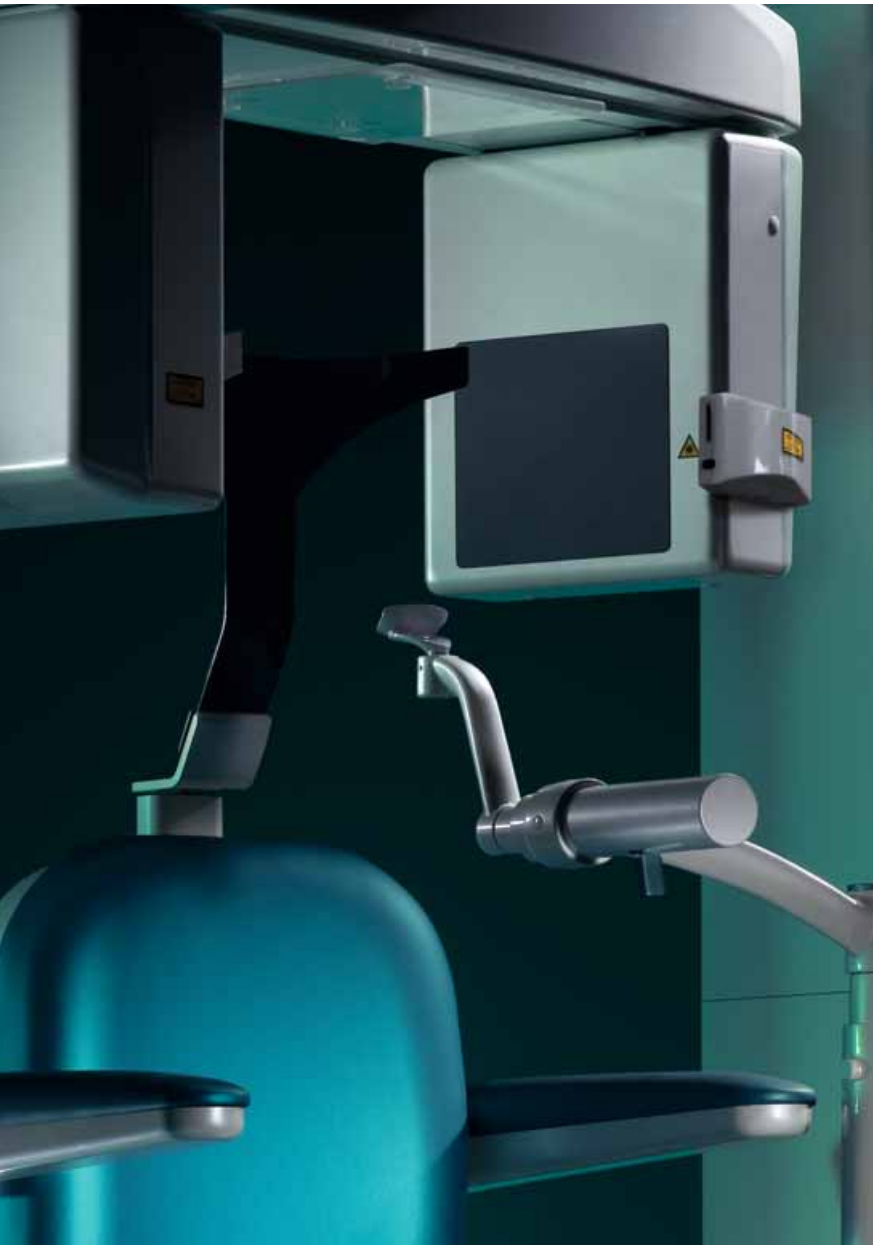These unique J. Morita applications let you view three dimensional images and volume rendered images even if the computer does not have i-Dixel software installed.

CT data can be exported from the i-Dixel application and later stored on a DVD.

This DVD can then be used on a computer outside the clinic to view CT images, volume rendered images and patient information.

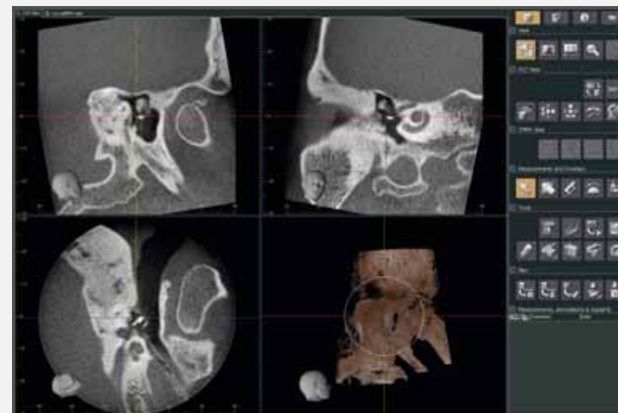
Additional functions include zoom, black and white reverse, brightness, and contrast adjustment as well as optional length and angle measurement capabilities.





i-Dixel Conforms to the Following DICOM Standards:

1. Modality worklist management service class
2. Storage service class
3. Modality performed procedure step service class
4. Print management service class



One Volume Viewer

Efficient Workflow Integration of DVT

i-Dixel Image Processing Software

It can be used as a database to archive a wide variety of image information. Its multiple image processing functions can easily access and manipulate many types of information for 2D and 3D images.

Volume Rendering

Volume rendering of CT data produces three dimensional images. Select the area of interest and adjust the controls for the histogram to create a detailed image of very fine structures.

Real Time Re-Slice

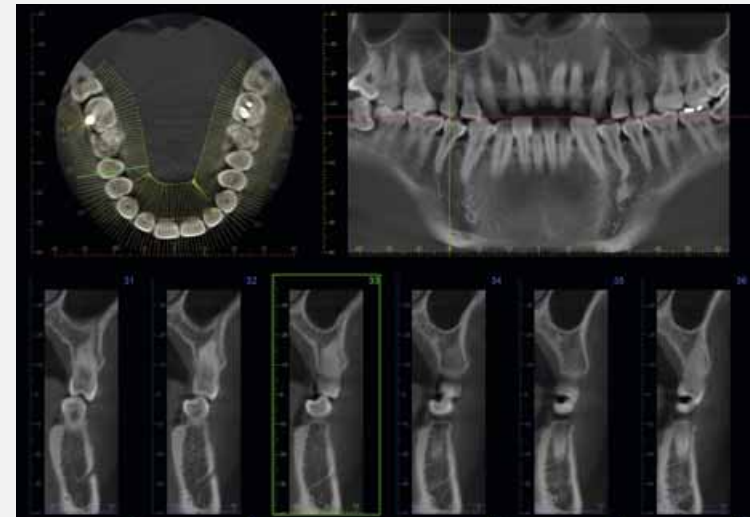
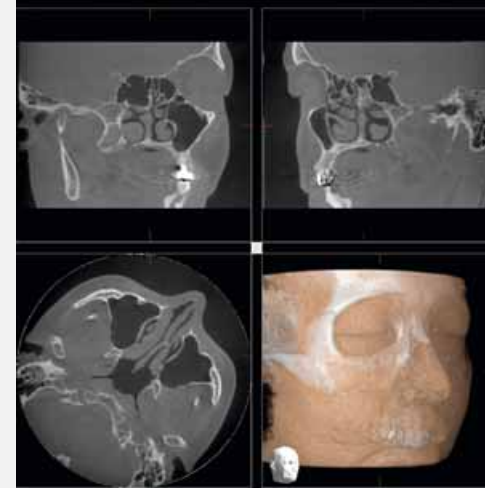
Slices and volume rendered images can be linked and easily manipulated in real time.

Curved MPR (cMPR)

This way of image processing allows you to observe an orthogonal representation of the dental arch or any arbitrary curve.

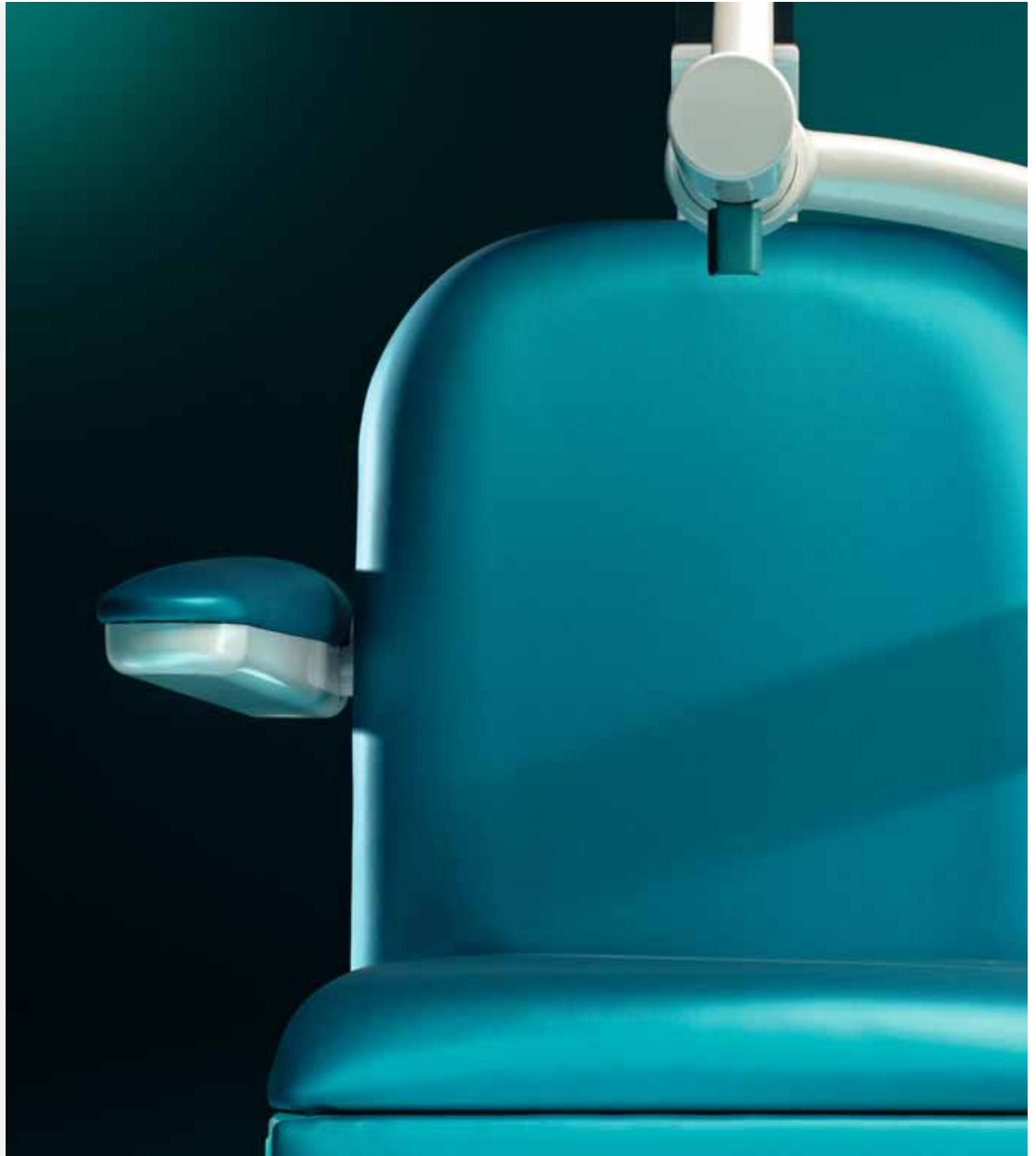
Report Comments

It is easy to enter comments for any image. These comments can be printed with a conventional Windows printer or a DICOM printer.



Report Comments

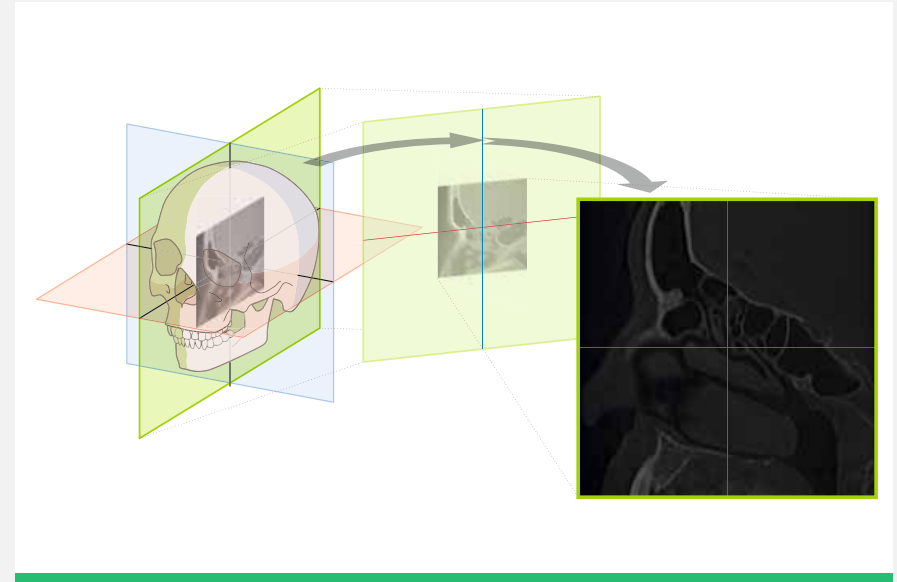
- XYZ view windows
- Re-slice
- Zoom
- Rotate
- Histogram
- Edge Enhancement
- Distance and Angle Measurement
- Negative Image
- Mirror Image
- Slice Distance Measurement
- Surface Rendering
- DICOM 3.0 Compatible
- Brightness Conversion
- Spatial Frequency Filter
- Patient Orientation Display
- Density Measurement



i-Dixel Image Processing Software

The Multiple Image Processing Functions and Easy Access


The arm rotates 360° around the center of the exposure region in 18 seconds (Standard Mode) as the x-ray head emits a cone-shaped beam. The multiple projections created during the arm's rotation are converted to a digital signal by the flat panel detector and transmitted to the computer. After any necessary supplemental or corrective processing, the digital information is converted into a three dimensional CT image using an image reconstruction algorithm, and a high resolution image appears on the computer's display. The voxel of 3D Accuitomo is an isotropic cube that produces images with equally fine detail in all three dimensions and minimizes artifacts produced by slice pitch and helical pitch; therefore resolution is never degraded by re-slicing. Conversely the rectangular voxel used for conventional CT imaging results in some image degradation when it is re-sliced. i-Dixel image processing software can be used as a database to archive a wide variety of image information. Its multiple image processing functions can easily access and manipulate many types of information for 2D and 3D images. These unique J. Morita applications let you view three dimensional images and volume rendered images. As a brochure can not offer this dynamic i-Dixel feature we added graphics which give orientation and show the position of the sagittal, coronal and axial plain.

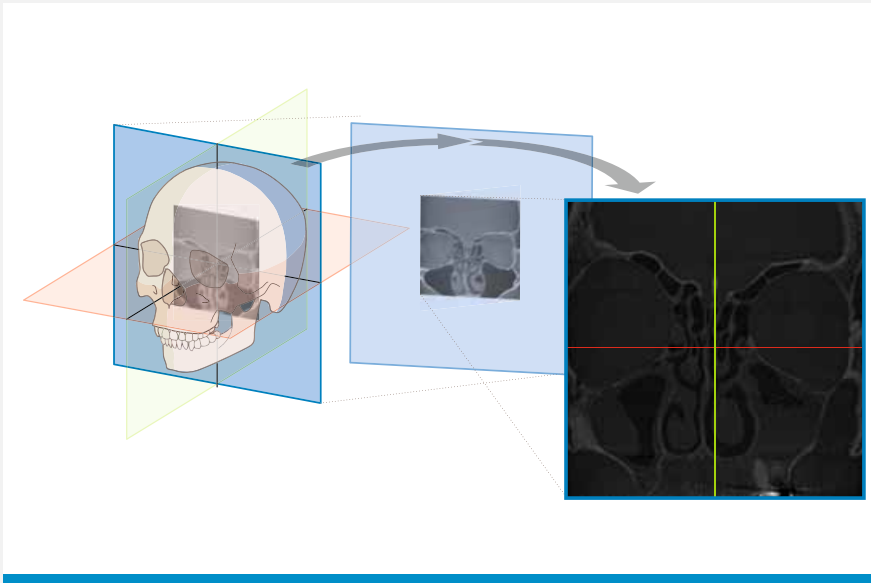


The X-Plain (Sagittal)

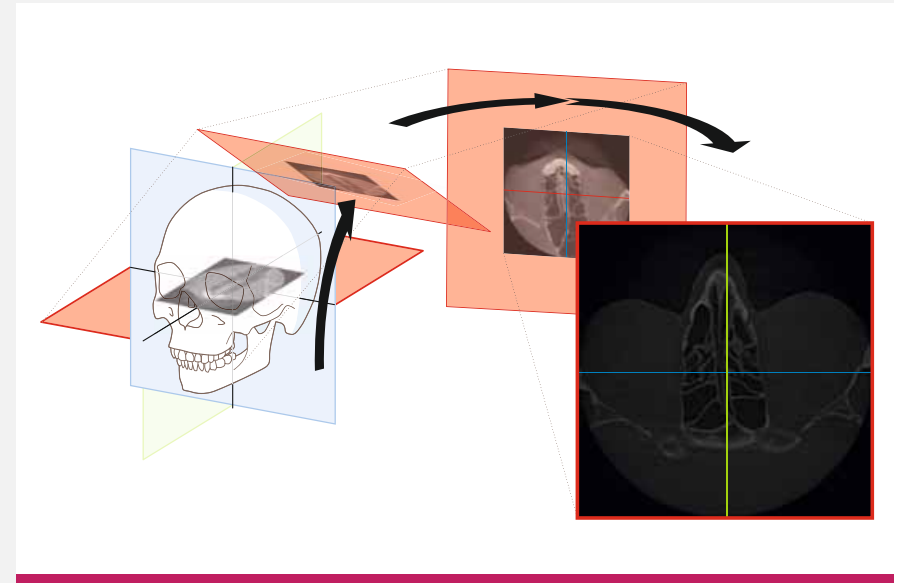
Degrees of Freedom (Two-Direction Scout)

The region of interest can be easily targeted by making images from two directions. Then by clicking on the center of the region the Accuitomo chair automatically moves into position.





The Y-Plane (Coronal)



The Z-Plane (Axial)

Temporal Bone Cases

Anatomy of the Temporal Bone in Digital Volume Tomography


Digital Volume Tomography can be used for the display of the complex three-dimensional anatomy in the temporal bone very well. This is due to the fact that DVT enables high resolution, low artifacts and 3 orthogonal plains in one examination. Possible indications for the DVT in temporal bone diagnostics can be inflammatory diseases, control of middle ear prosthesis and cochlear implants as well as the evaluation of the inner ear itself. The absolute precondition of successful use of DVT in the lateral skull base are excellent skills of the sophisticated three-dimensional anatomy of the temporal bone.

The axial plain is used best for the imaging of the following structures of the temporal bone: malleus head and neck, incus body, malleoincudal joint, incudostapedial joint, pneumatization of the mastoid, sigmoid sinus, facial recess, tympanic sinus, pyramidal eminence.

The coronal plain is suitable for the evaluation of the long process of the incus, malleus manubrium, internal carotid artery, tympanic segment of the facial nerve. The sagittal plain is favoured in the display of the mastoid portion of the facial nerve as well as the semicircular canals. It also enables analogical orientation to mastoidectomy.

Digital Volume Tomography can be also useful in the diagnosis of inflammatory diseases, such as acute or chronic mastoiditis, cholesteatoma or postinflammatory conductive hearing loss where osseous destructions can be well evaluated. Also in cases of erosion of the labyrinth DVT is a useful diagnostic modality.

The position of the laser target beams for the display of the temporal bone is shown in the figure on page 3. The beams are oriented to the temporal line, the posterior wall of the external auditory canal and the lateral corner of the eye.

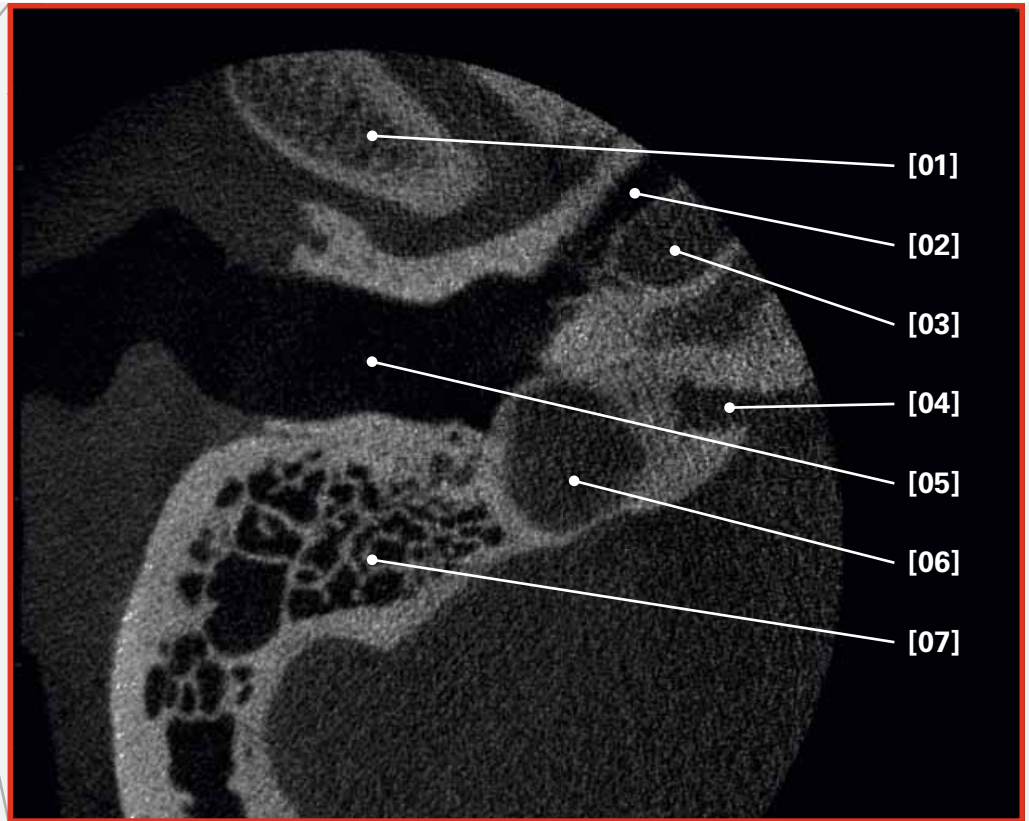
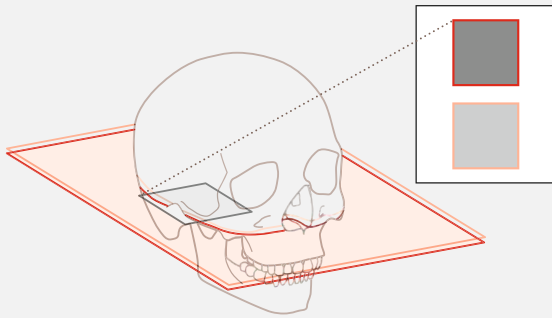


Positioning of the laser target beams at the lateral skull base.

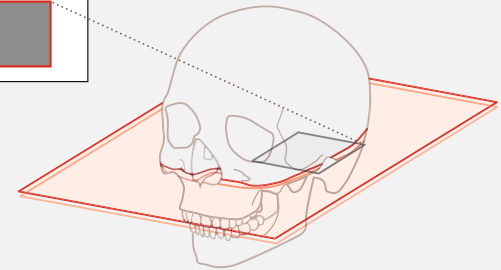
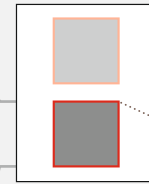
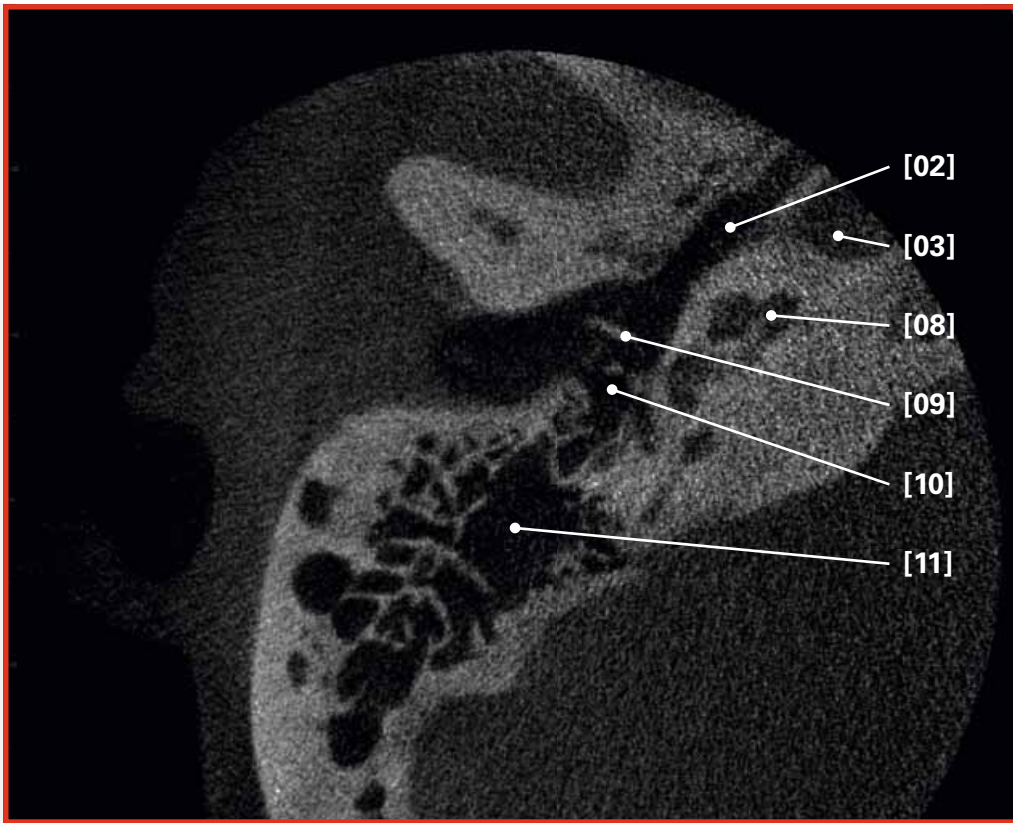
The favourable projections are summarised in the following table:

Structure	Best projection		
	axial	coronal	sagittal
Malleus manubrium		X	
Malleus neck	X	X	
Malleus head	X	X	
Malleoincudal articulation	X		
Incus lenticular process	X		
Incus long process		X	
Incus body	X		
Incudostapedial articulation	X		
Stapes suprastructure	X		
Stapes footplate	X	X	
Attic		X	
Antrum	X		
Pneumatisation of the Mastoid	X		
Tegmen		X	X
Sigmoid sinus	X		
Round window		X	
Facial nerve (horizontal segment)		X	
Facial nerve (vertical segment)			X
Semicircular canals			X

Axial Plain, caudal

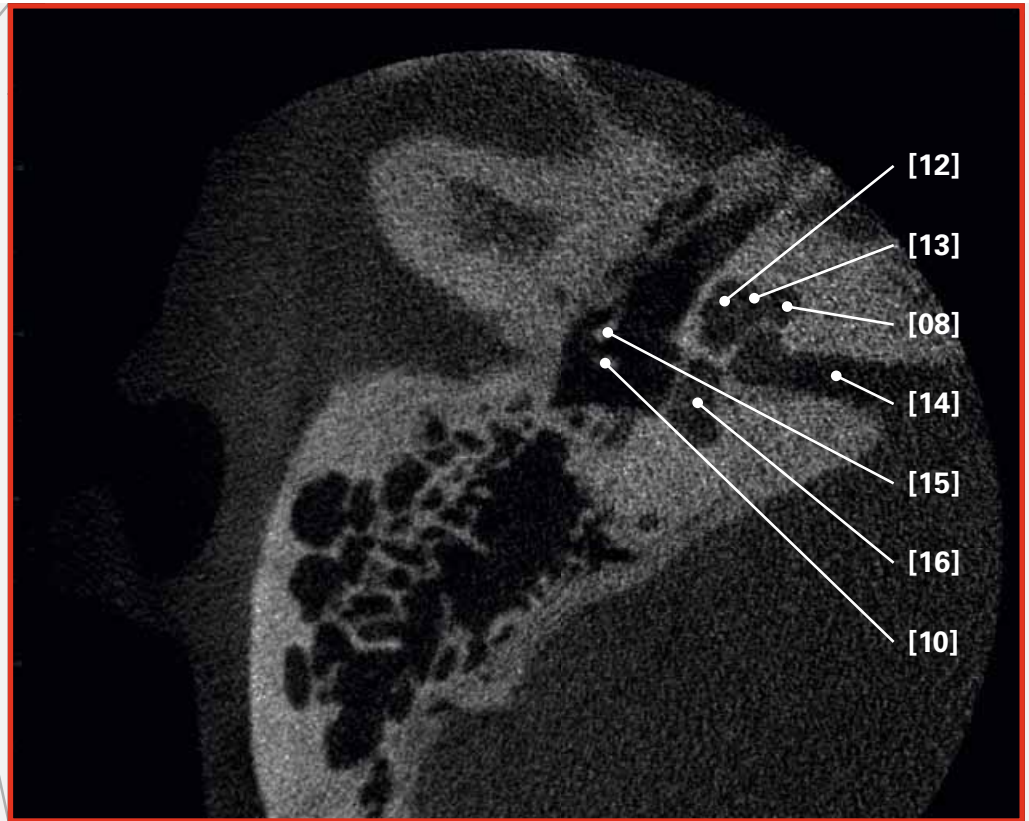
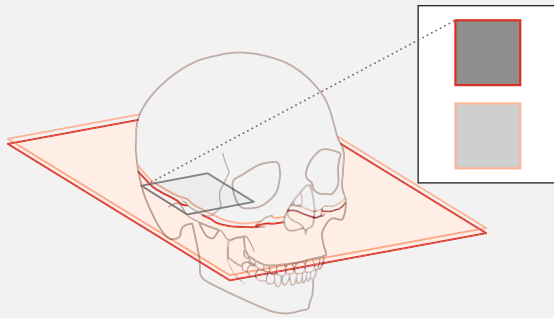


- [01] Temporomandibular joint
- [02] Eustachian tube
- [03] Internal carotid artery
- [04] Cochlear aqueduct
- [05] External auditory canal
- [06] Sigmoid sinus
- [07] Mastoid cells

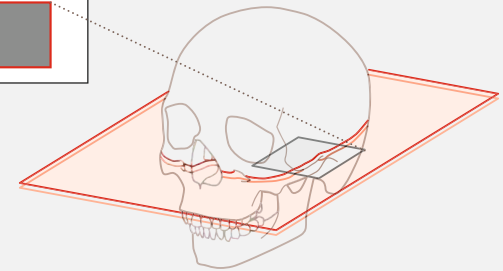
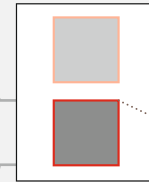
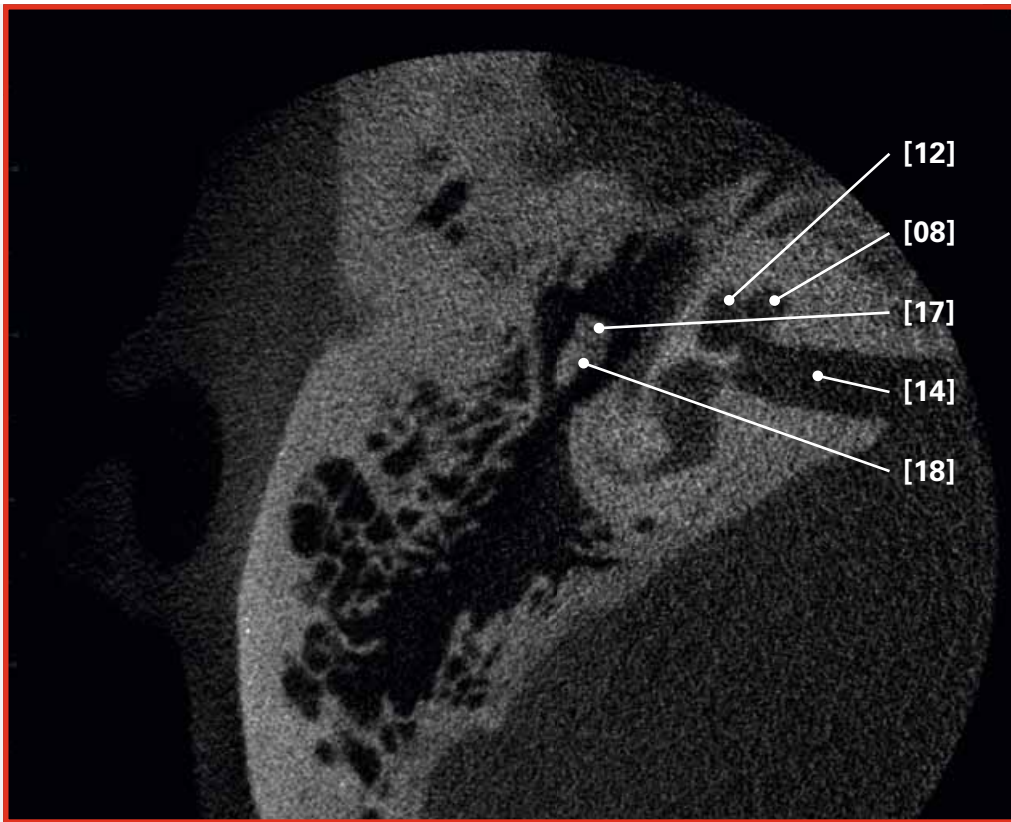


- [02] Eustachian tube
- [03] Internal carotid artery
- [08] Basal turn of cochlea
- [09] Manubrium mallei
- [10] Long process of incus
- [11] Facial recessus

Axial Plain, cranial

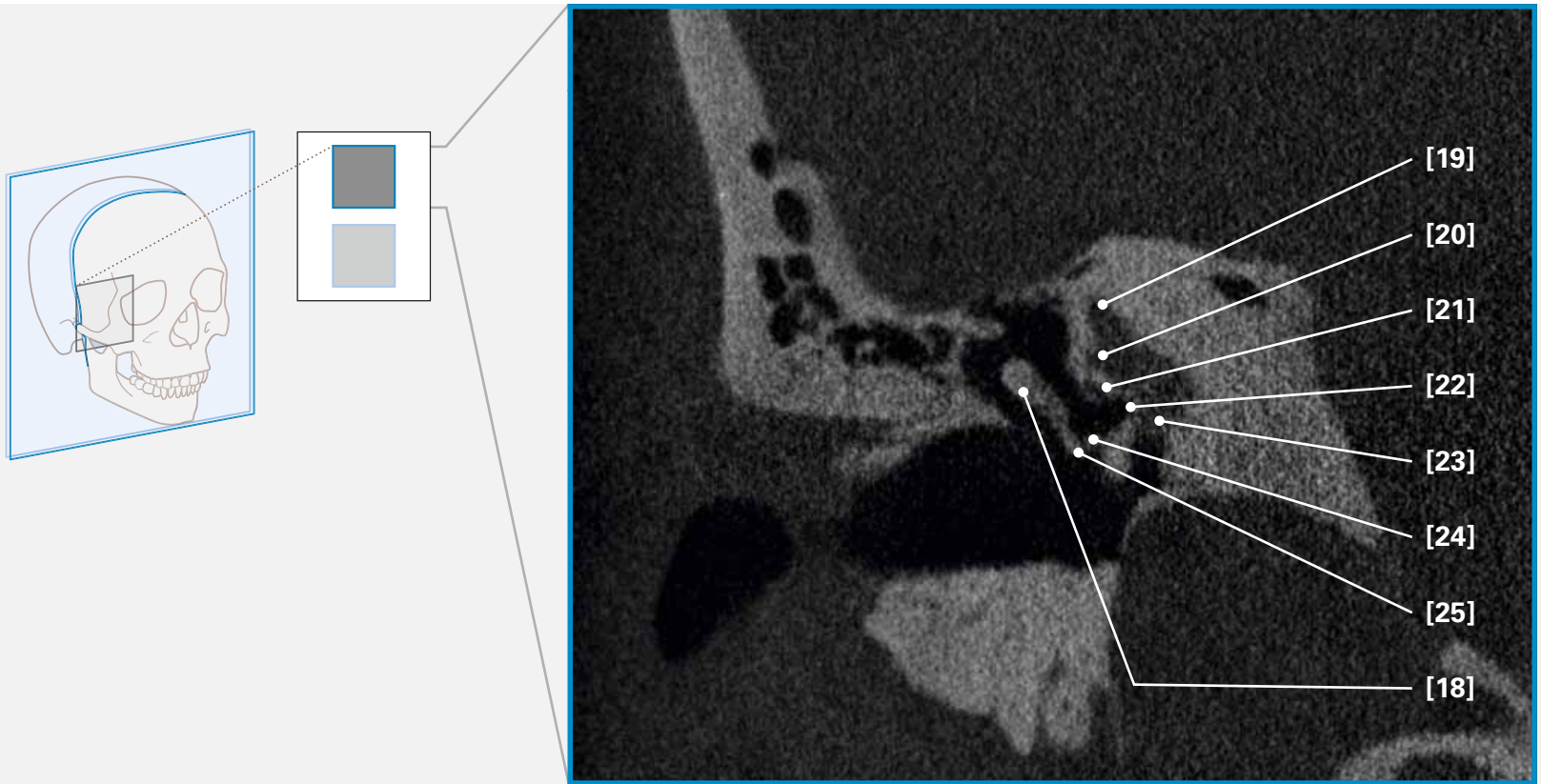


- [08] Basal turn of cochlea
- [10] Long process of incus
- [12] Apical turn of cochlea
- [13] Middle turn of cochlea
- [14] Internal auditory canal
- [15] Malleus neck
- [16] Vestibulum



- [08] Basal turn of cochlea
- [12] Apical turn of cochlea
- [14] Internal auditory canal
- [17] Malleus head
- [18] Incus body

Coronal Plain, from anterior to posterior



[18] Incus body

[19] Superior semicircular canal

[20] Horizontal semicircular canal

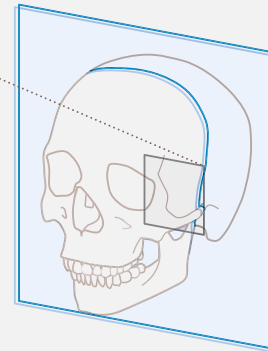
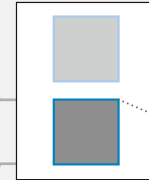
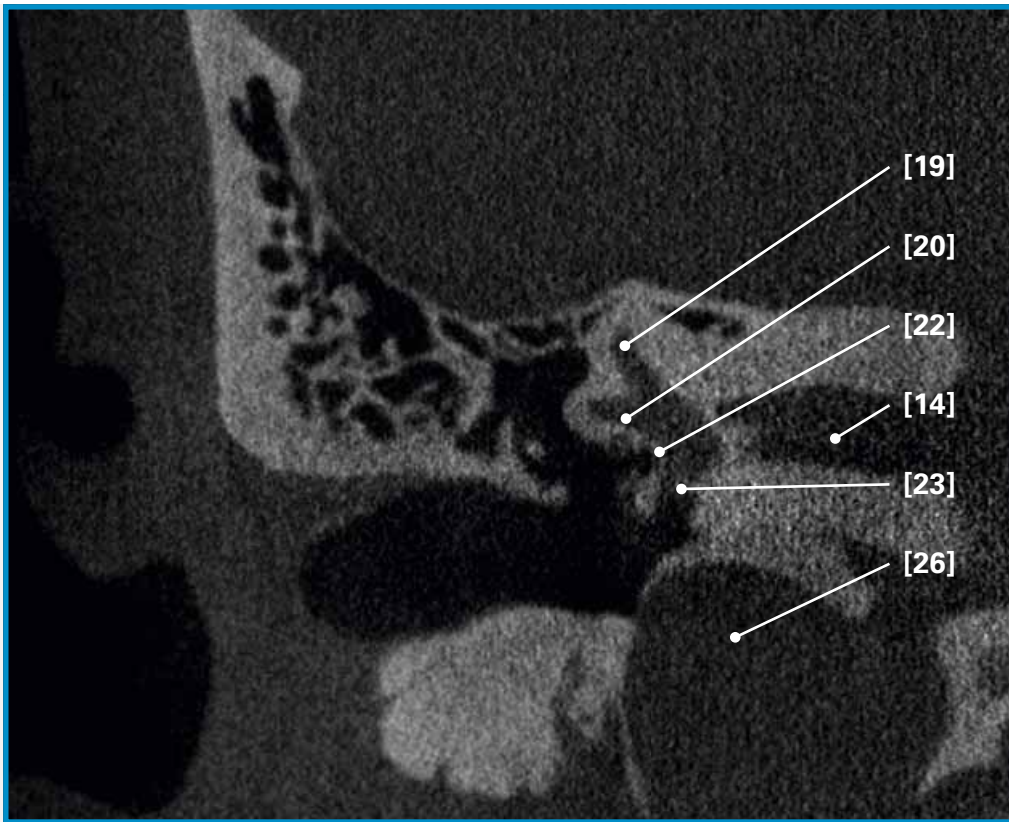
[21] Facial nerve (tympanic segment)

[22] Oval window

[23] Round window

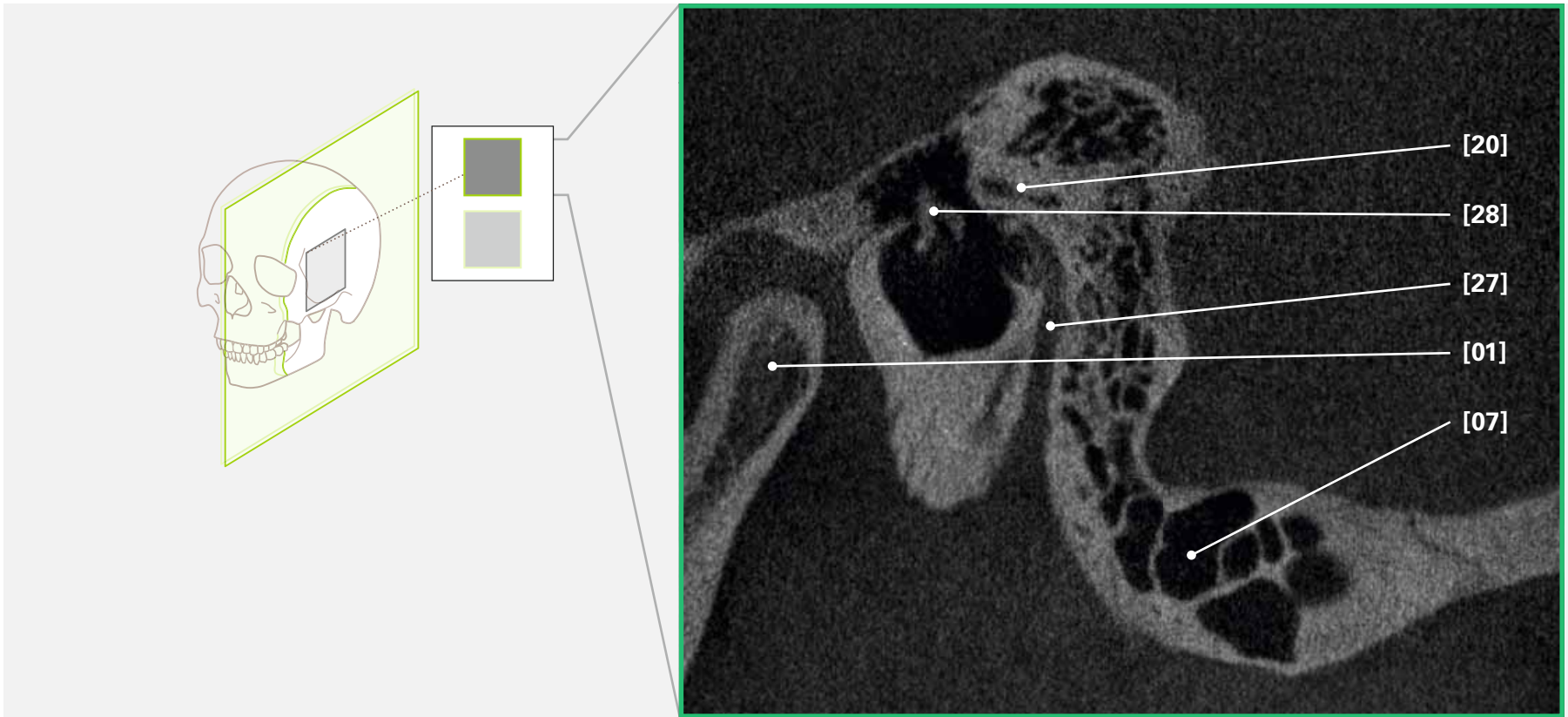
[24] Stapes

[25] Incudostapedial joint



- [14] Internal auditory canal
- [19] Superior semicircular canal
- [20] Horizontal semicircular canal
- [22] Oval window
- [23] Round window
- [26] Bulbus venae jugularis

Sagittal Plain, from lateral to medial



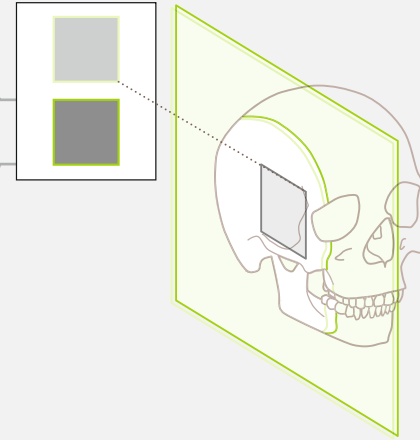
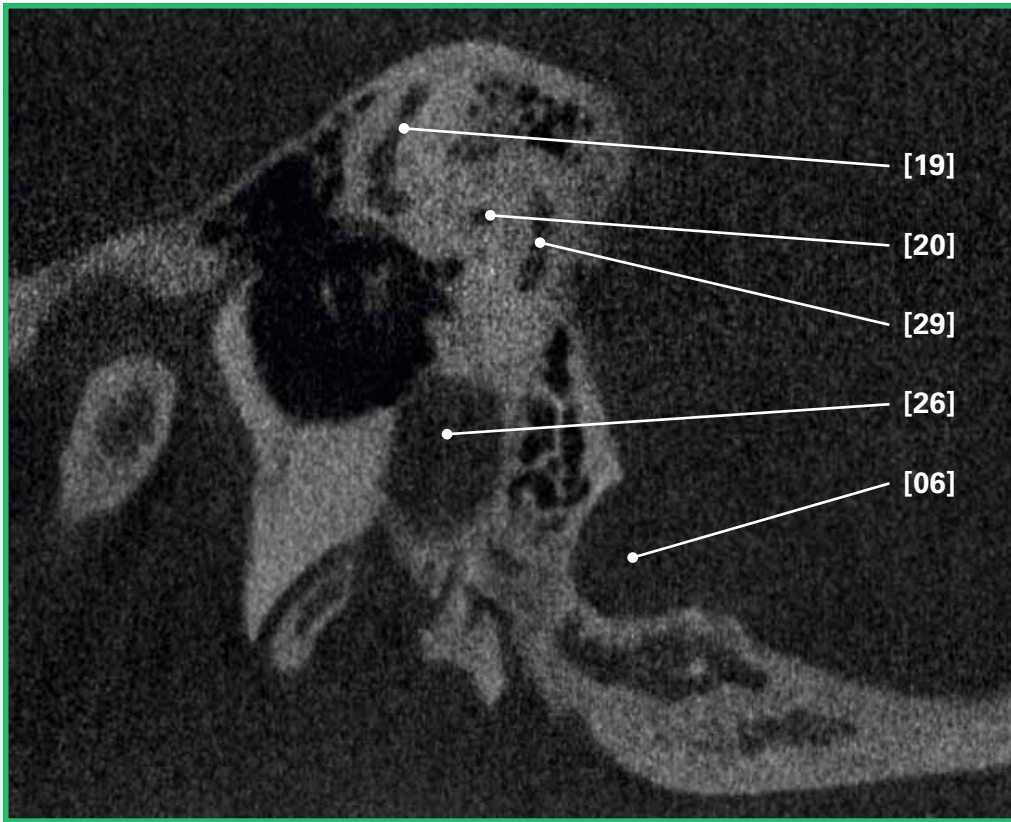
[01] Temporomandibular joint

[07] Mastoid cells

[20] Horizontal semicircular canal

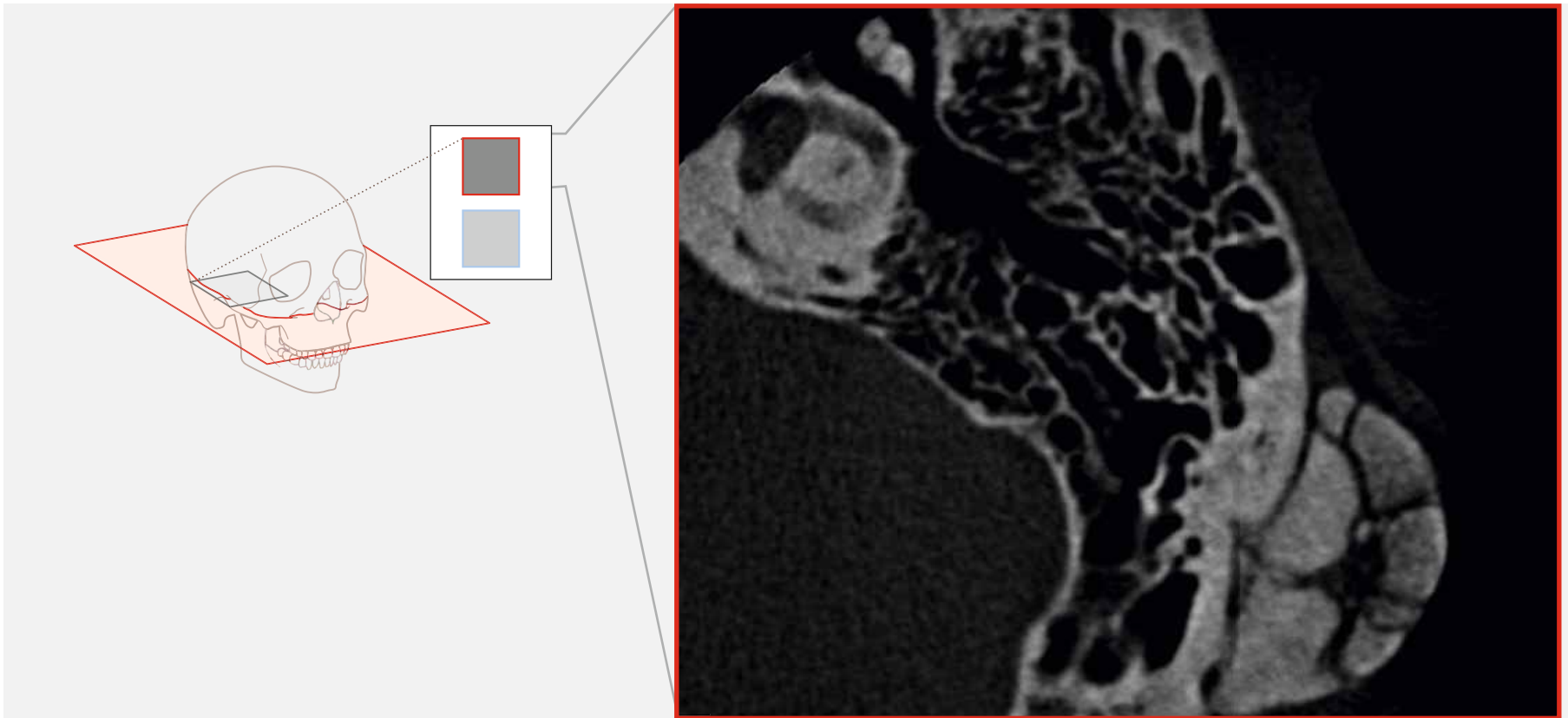
[27] Facial nerve (mastoid segment)

[28] Amblymalleal joint

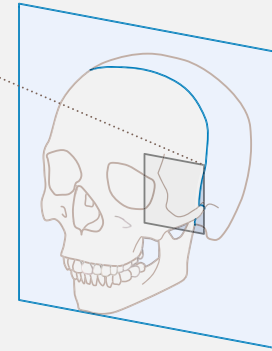
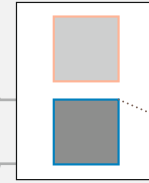
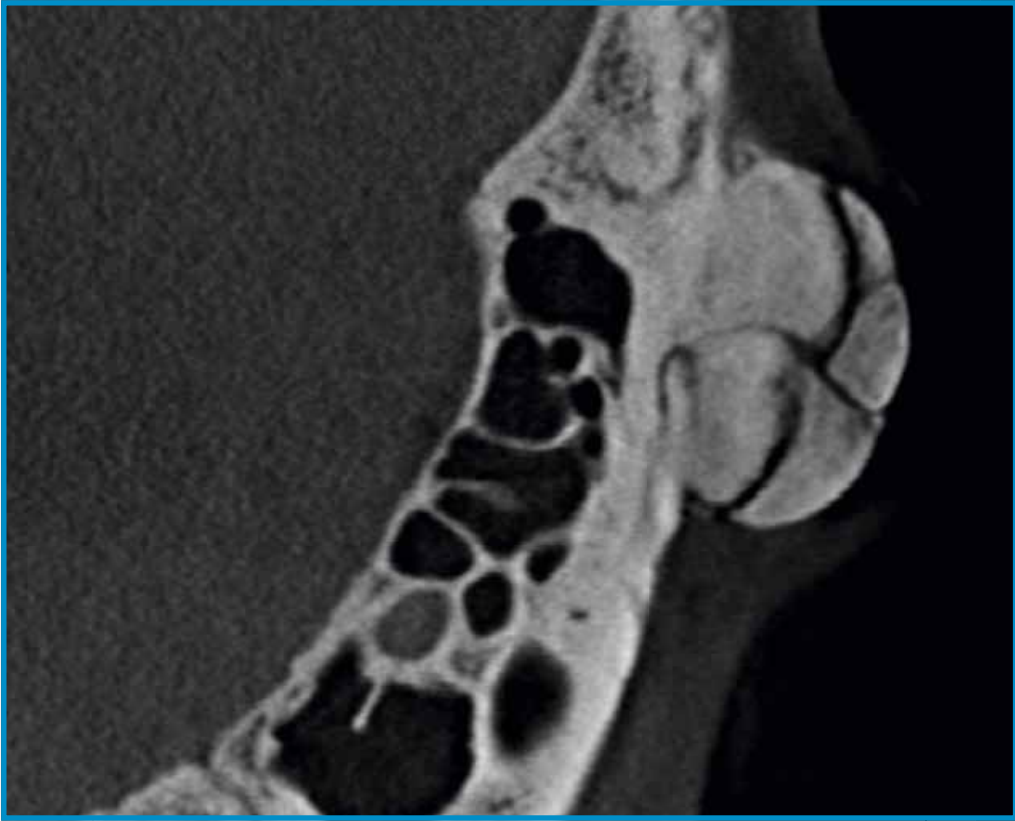


- [06] Sigmoid sinus
- [19] Superior semicircular canal
- [20] Horizontal semicircular canal
- [26] Bulbus venae jugularis
- [29] Posterior semicircular canal

Osteoma of temporal bone



Case: The patient reported a swelling behind the left ear, which exists since more than 10 years with very slow growing. Now he wished the operative extirpation, so a cone beam tomography was done. The pictures show a osteoma of the temporal bone. History confirmed this diagnosis.



Anterior Skull Base Cases

Anatomy of the Anterior Skull Base in Digital Volume Tomography

Digital Volume Tomography shows the bony anatomy very well and is able to give a roadmap for paranasal sinus surgery. The main indications for cross section imaging in the field of the anterior skull base are:

- Suspected intracranial or intraorbital complications of a rhinosinusitis.
- Suspected atypical infections or neoplasms.
- Specific pathological conditions, such as mucoceles, benign tumors to confirm the extent of the lesion.
- In the case of planned optical nerve or orbital decompression.

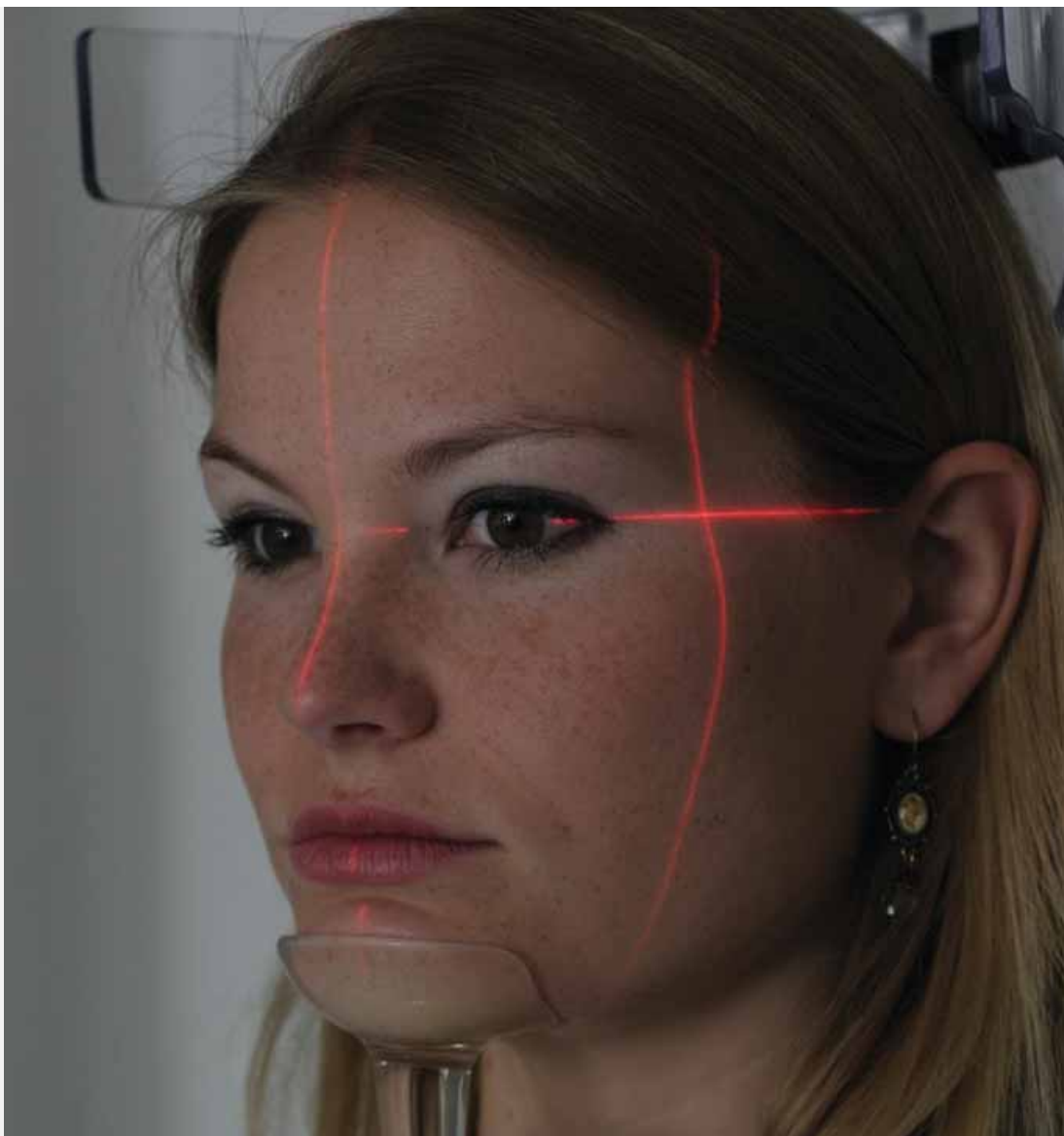
Since the introduction of the enlarged cylindrical volume Digital Volume Tomography can be also used for the evaluation of the paranasal sinuses and its surrounding structures. The anatomical key structures are clearly identifiable using DVT-scans of a volume of 10x10 cm from the anterior nasal spine to the posterior wall of the sphenoid sinus. DVT can also be used in cases of nasal bone fractures and blow-out-fractures very well. DVT in the case of rhinosinusitis should be performed only in cases after sufficient medical treatment to confirm the chronic residual disease that has to be treated surgically, if the above mentioned conditions are not fulfilled.

The coronal plain is used as the standard plain for this purpose as we know from CT scans for the evaluation of the sinuses from anterior to posterior with the nasolacrimal duct, agger nasi, uncinat process, bulla ethmoidalis, anterior ethmoidal artery, septum and turbinates.

The sagittal plain is an excellent completion for the display of the frontal recess and duct, the course of the skull base and the infraorbital nerve, in the cases of fractures of the nasal bone and the orbital floor as well as for the evaluation of the anterior ethmoidal artery.

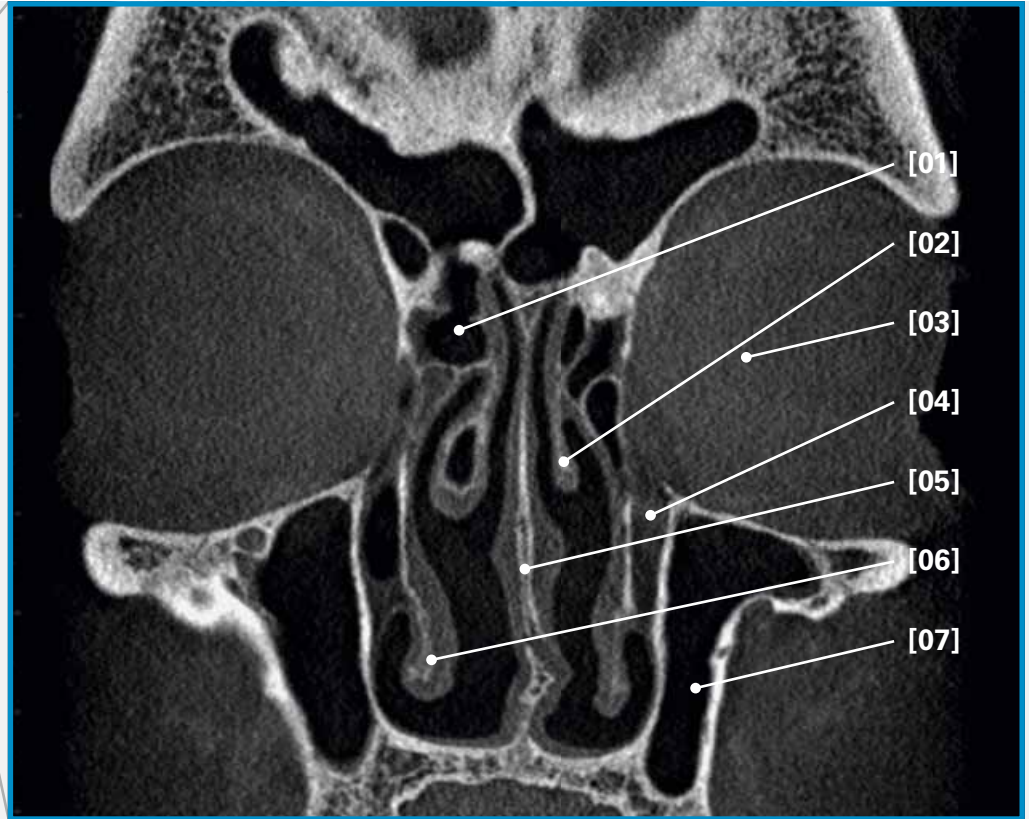
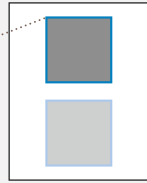
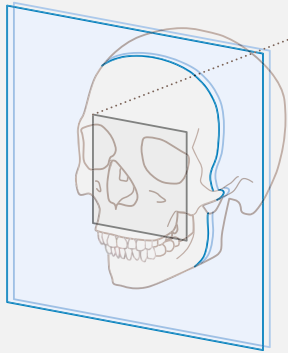
The axial plain is used best for the diagnosis of fractures (maxillary sinus, nasal bone) or for the extent of inflammatory diseases at one glance.

The laser target beams should be positioned as the following figure shows to gain sufficient display of the paranasal sinuses. Of course the individual anatomy or the diagnostic purpose has to be considered.

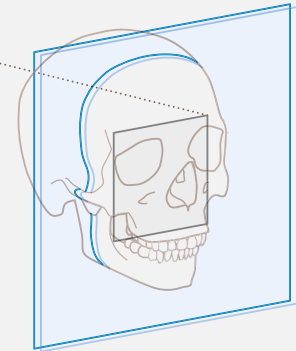
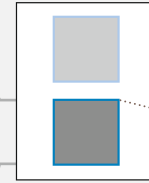
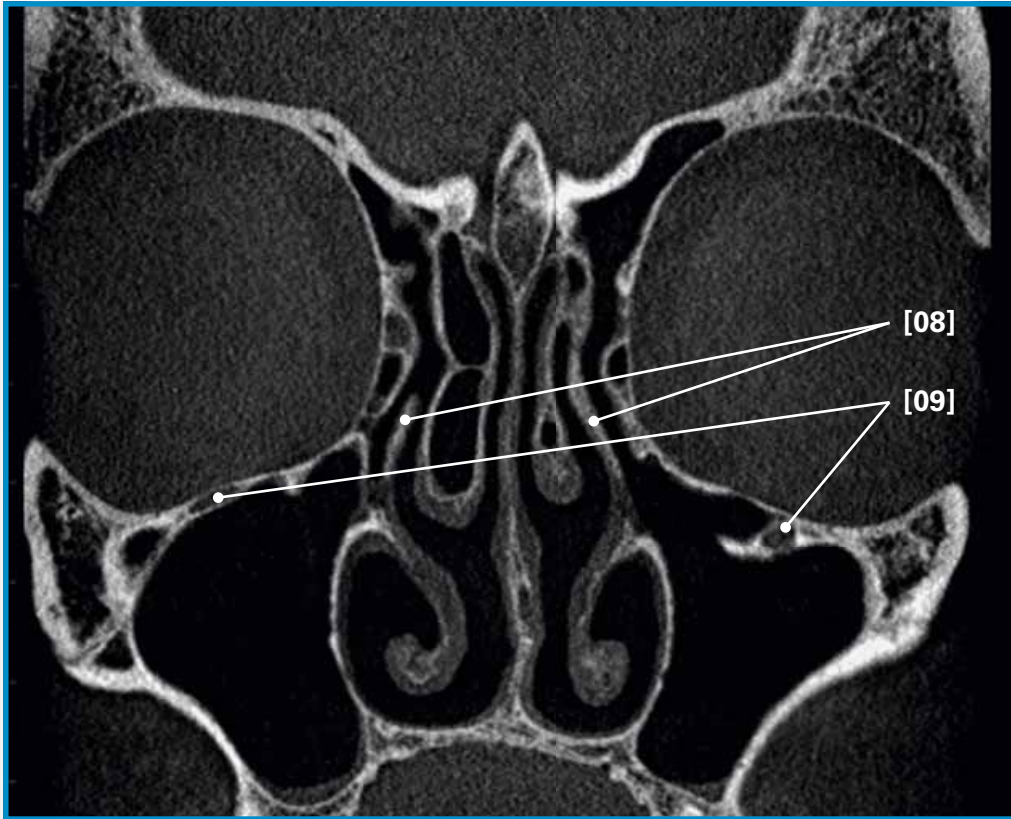


Positioning of the laser target beams in the case of a DVT of the paranasal sinuses.

Coronal Plain, from anterior to posterior



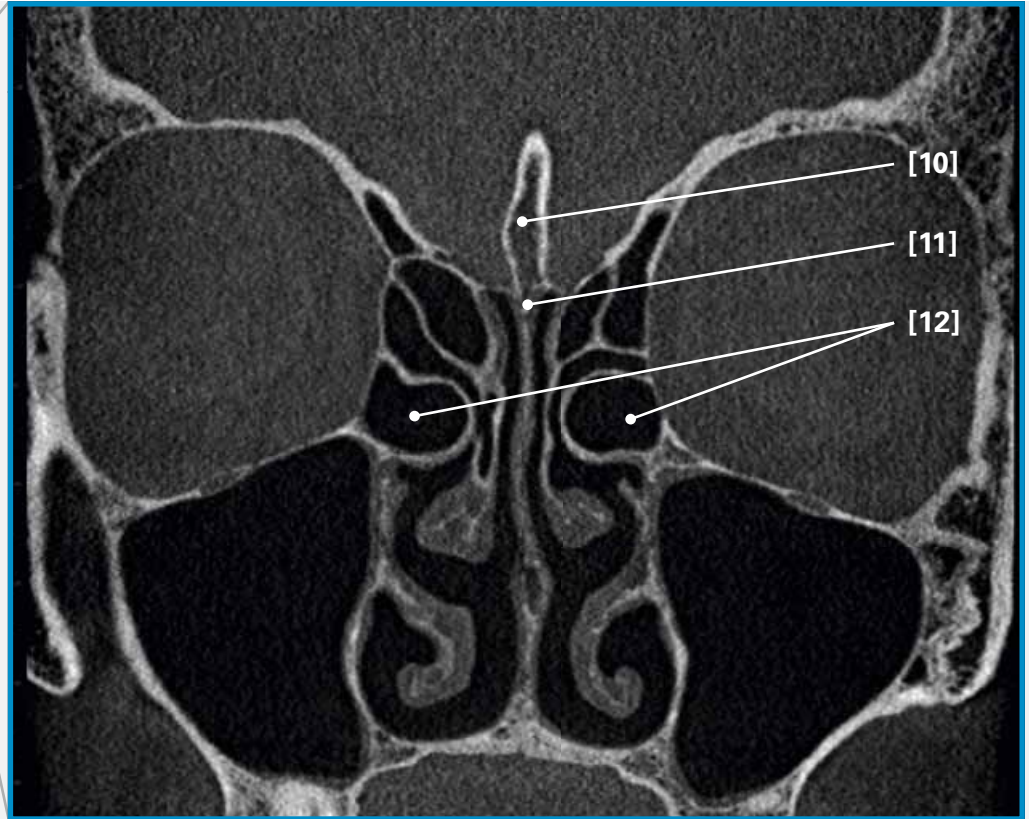
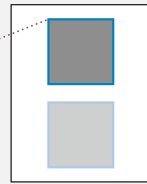
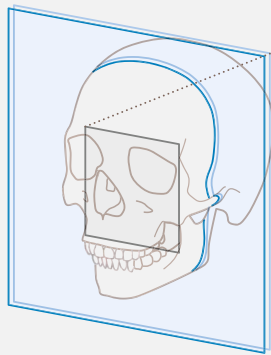
- [01] Aggar nasi cell
- [02] Middle turbinate
- [03] Orbit
- [04] Nasolacrimal duct
- [05] Septum
- [06] Inferior turbinate
- [07] Maxillary sinus



[08] Uncinate process

[09] Infraorbital nerve

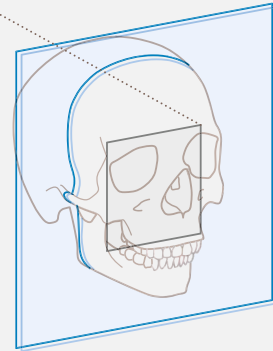
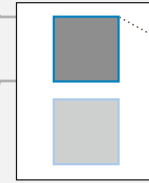
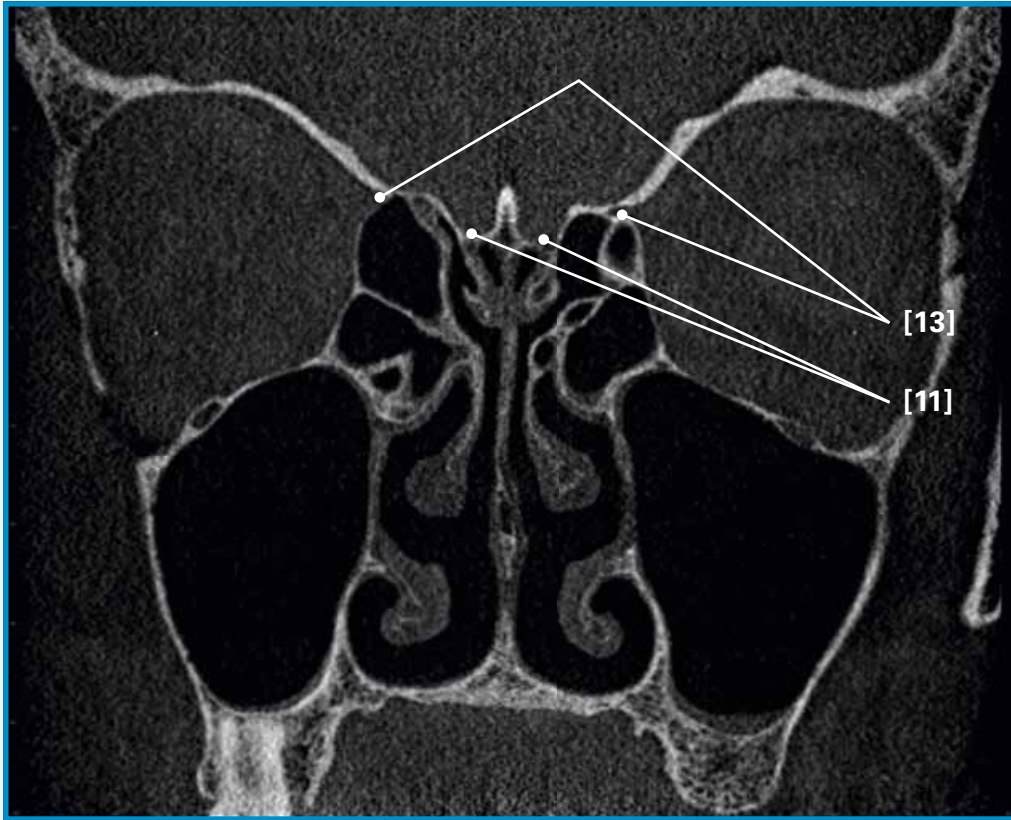
Coronal Plain, from anterior to posterior



[10] Christa galli

[11] Lamina cribrosa

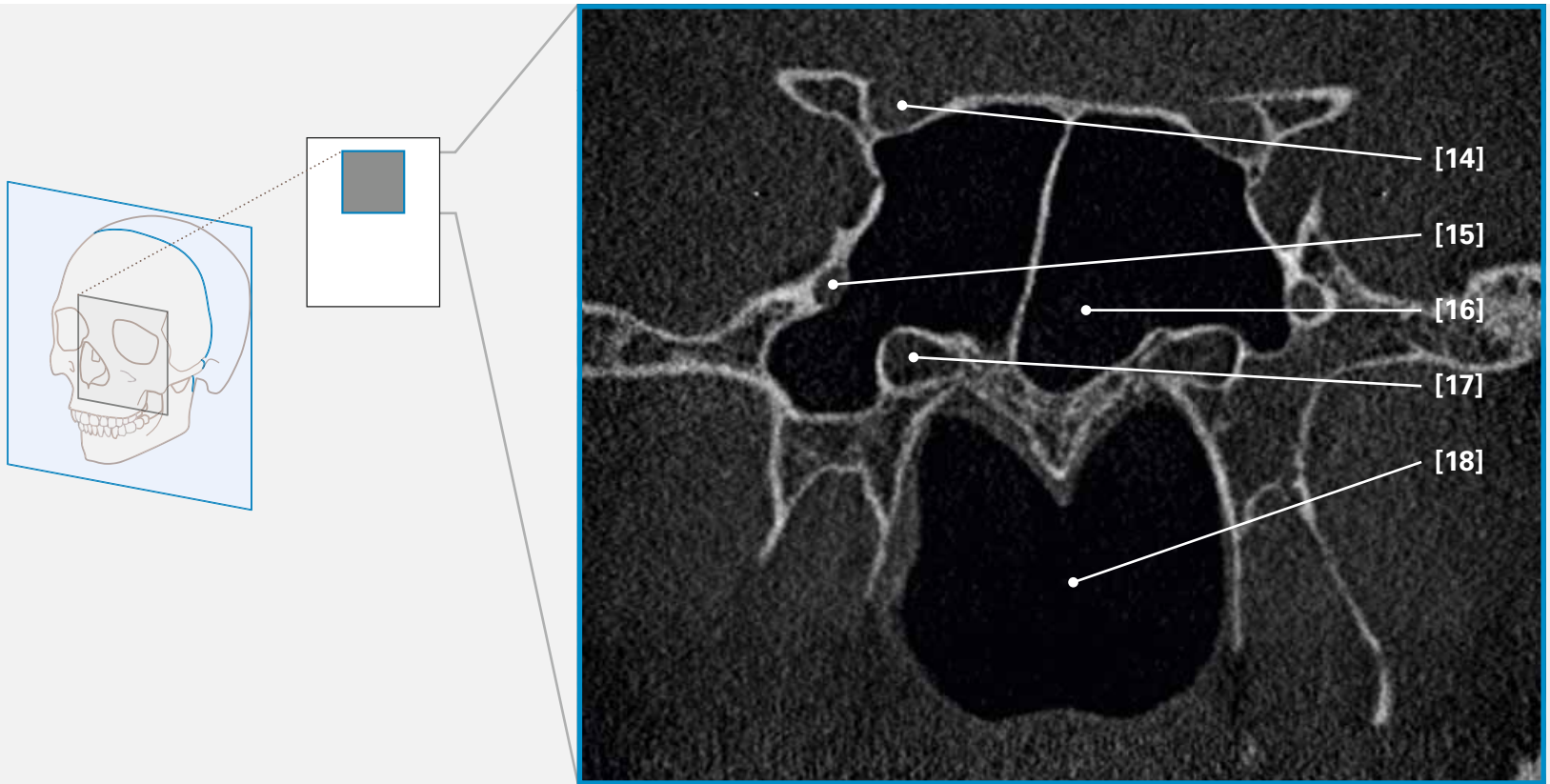
[12] Bulla ethmoidalis



[11] Lamina cribrosa

[13] Anterior ethmoid artery

Coronal Plain , from anterior to posterior




[14] Optic nerve

[15] Foramen rotundum

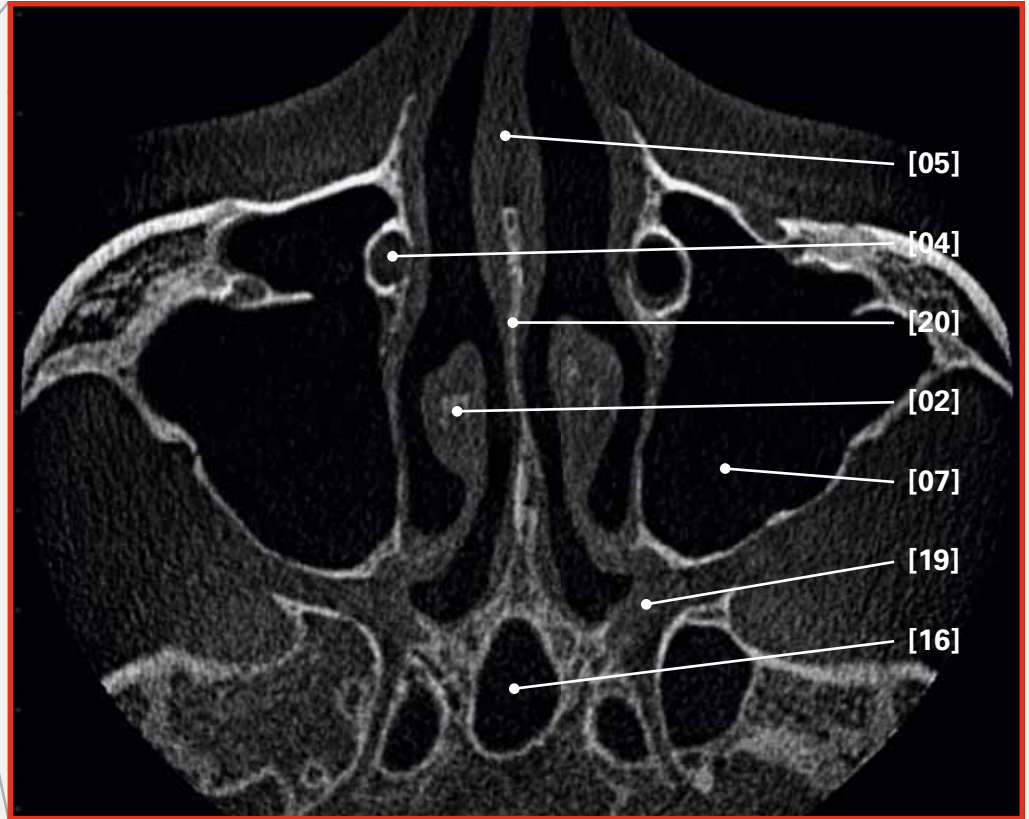
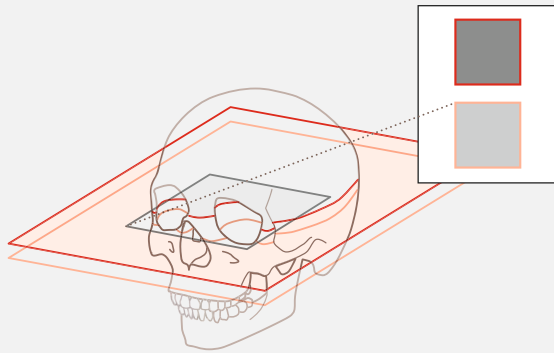
[16] Sphenoid sinus

[17] Vidianus nerve

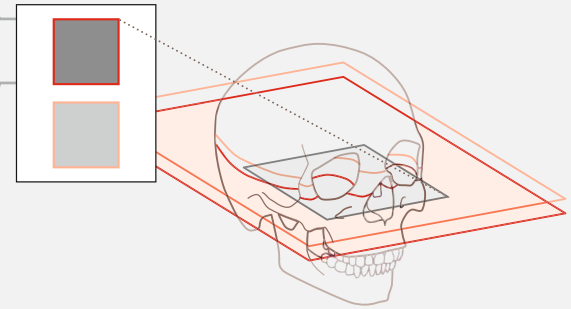
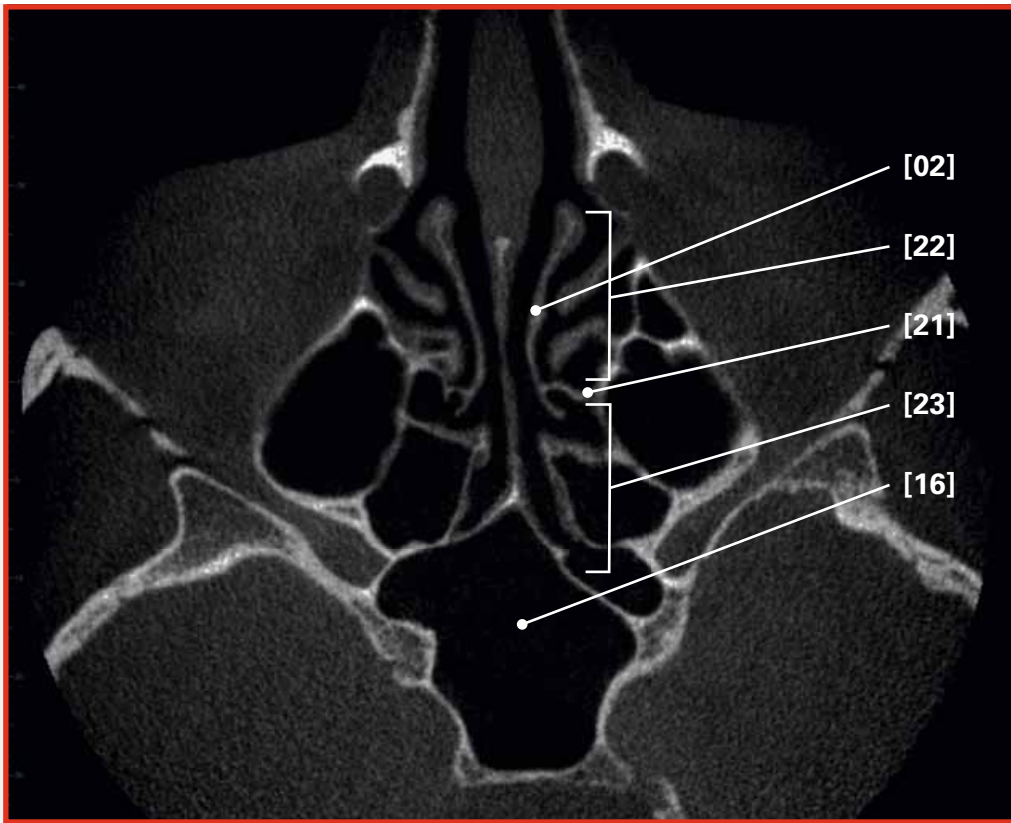
[18] Nasopharynx



Axial Plain



- [02] Middle turbinate
- [04] Nasolacrimal duct
- [05] Septum
- [07] Maxillary sinus
- [16] Sphenoid sinus
- [19] Foramen sphenopalatinum
- [20] Vomer



[02] Middle turbinate

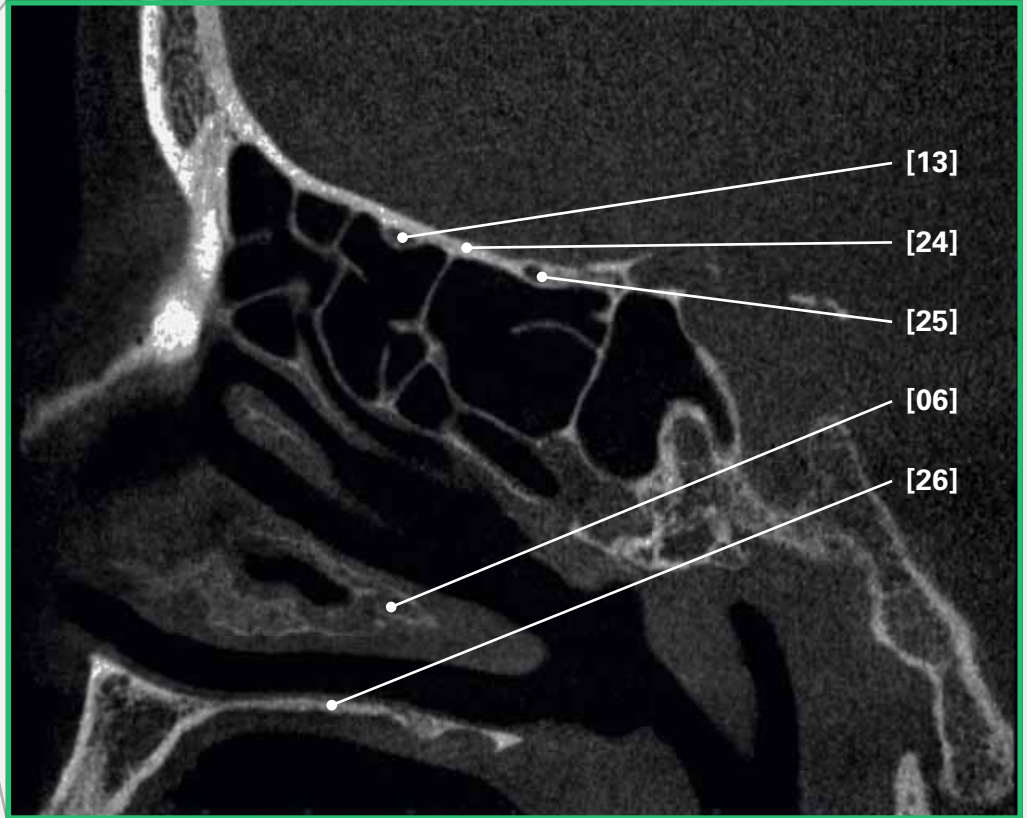
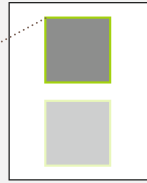
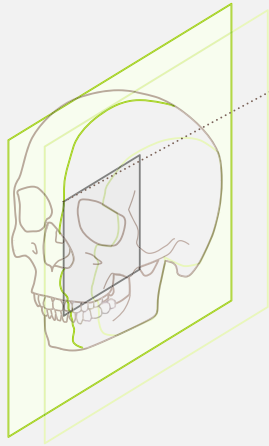
[16] Sphenoid sinus

[21] Basal lamella of middle turbinate

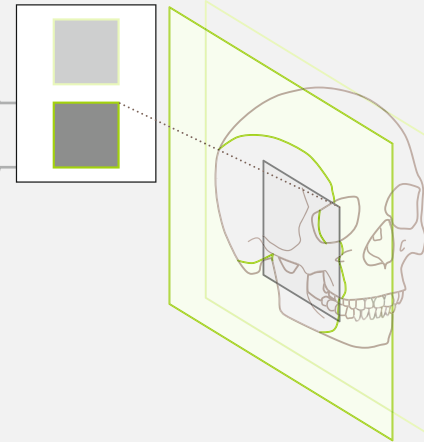
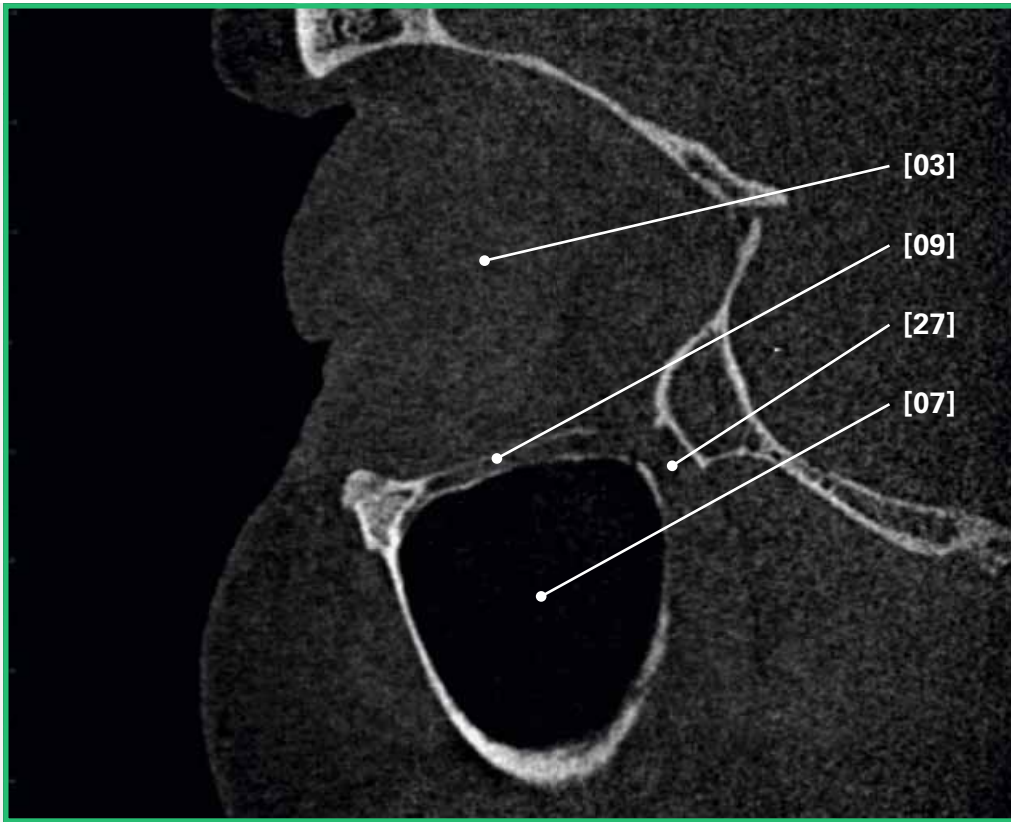
[22] Anterior ethmoid cells

[23] Posterior ethmoid cells

Sagittal Plain

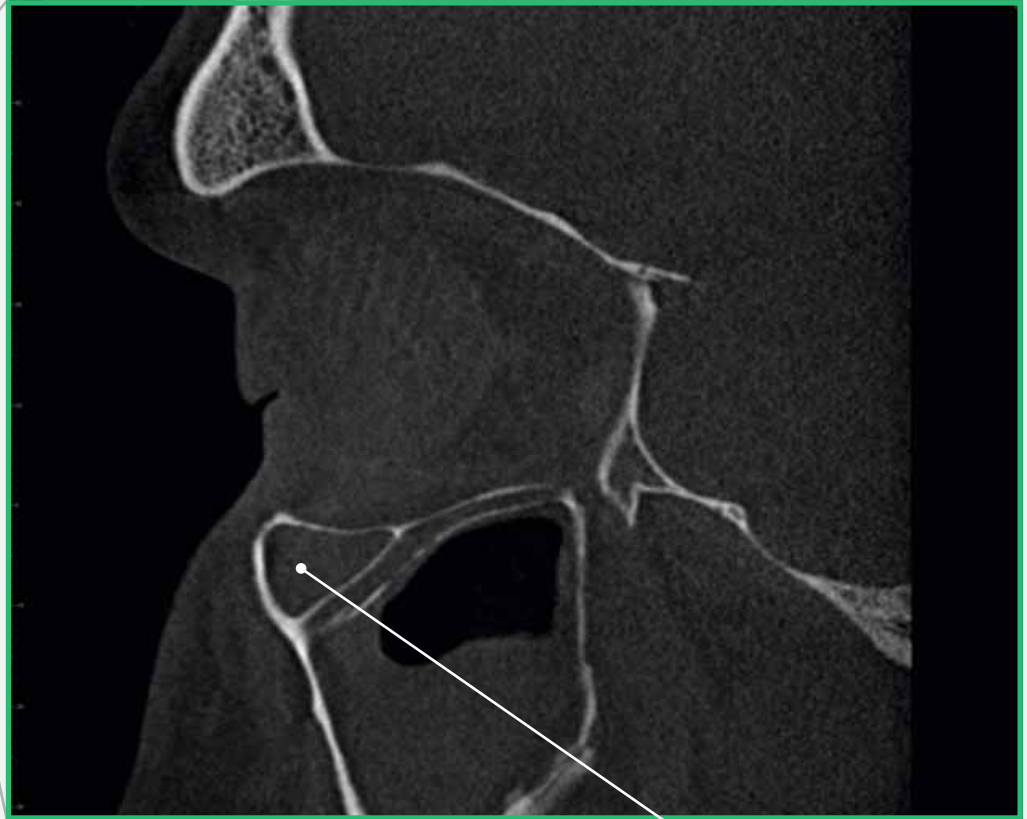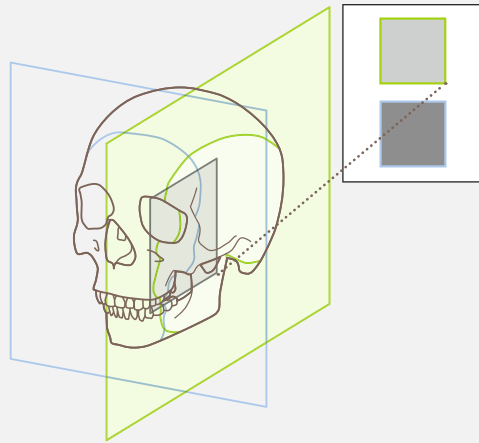


- [06] Inferior turbinate
- [13] Anterior ethmoid artery
- [24] Anterior skull base
- [25] Posterior ethmoid artery
- [26] Hard palate

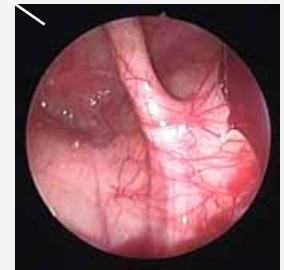

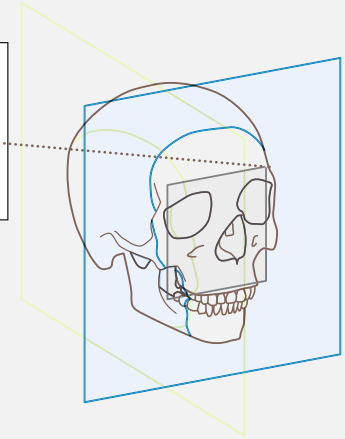
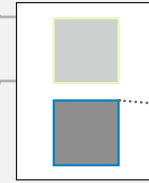
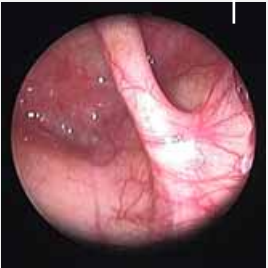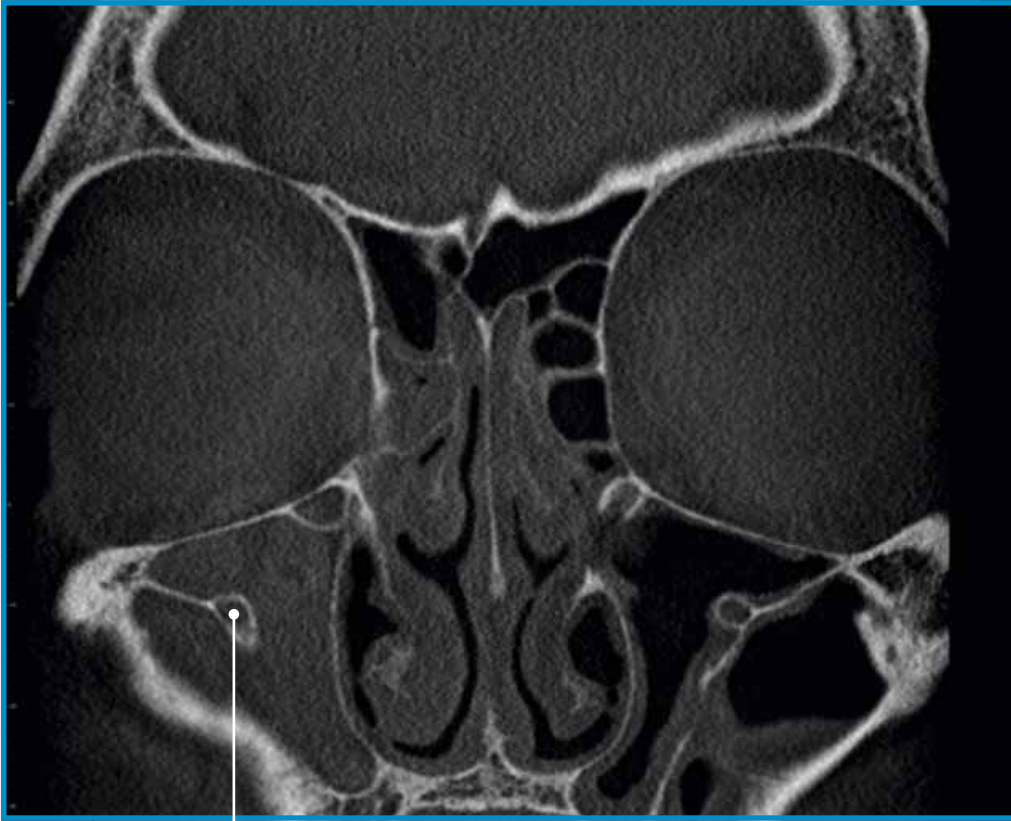- [03] Orbit
- [07] Maxillary sinus
- [09] Infraorbital nerve
- [27] Fossa pterygopalatina

Nose and paranasal sinus



Case: The patient reported about a chronic pain on the right maxillary sinus. Before the planned endonasal sinus surgery a cone beam tomography of nose and paranasal sinus were performed. A free bony course of the nervus infraorbitalis through the pathology of the right maxillary sinus could be seen. [This status was also seen in intraoperative endoscopic view]





Thinking ahead. Focused on life.

The slogan of Morita literally accompanies us in our decisions. Characterized by Japanese roots, we are setting forth the tradition of working to precision under highest quality demands. This is reflected in the complete product portfolio and shows that each individual product has been thought through in the finest detail. The art of manufacturing high-performance and sophisticated products has been used to considerable benefit by Morita in the course of the company's history and has enabled Morita to establish itself as one of the leading manufacturers of medical-technical products. Our passion for perfection is a guarantee for comfort and efficiency in the day-to-day running of a doctor's practice. A precondition for this is that we know what users need and that is exactly why working in cooperation with them as partners is so important to us. This provides us with a precise idea of their specific needs and we use this as a starting point in order to create practical innovations. In doing so, we are permanently thinking beyond our own limits and develop new ideas in order to set new trends.

Developed and manufactured by

J. Morita Mfg. Corp.

680 Higashihama Minami-cho
Fushimi-ku, Kyoto
612-8533 Japan

Tel.: +81 75 / 605-2323
Fax: +81 75 / 605-2355
jm-med@jmorita-mfg.co.jp
www.jmorita-mfg.com

Distributed by

J. Morita Europe GmbH

Justus-von-Liebig-Str. 27a
63128 Dietzenbach, Germany

Tel.: +49 6074 / 836 - 0
Fax: +49 6074 / 836 - 299
info@morita.de
www.morita.com/europe

Individual details of product illustrations in this leaflet may differ from the current product range. Optional equipment is occasionally illustrated at additional cost. Subject to technical modifications. Errors and omissions excepted. Printed in Germany. Subject to technical changes and errors, Printed in Germany, JME PUB 35325 0811 *8.

Thinking ahead. Focused on life.

