



## **3D IMAGE CLINICAL CASES - ENDODONTICS**

---

# CONTENTS

■ ENDODONTICS.....	3
■ TOOTH FRACTURE.....	15
■ LATERAL LUXATION.....	18
■ INTERNAL RESORPTION.....	19
■ ENAMEL DROP.....	23

Supervised by Yoshinori Arai, DDS, PhD  
Professor Nihon University  
School of Dentistry

Clinical images are provided by:  
(Listed in alphabetical order)

L. Stephen Buchanan, DDS, FICD, FACD

Alan H. Gluskin, DDS, Professor and Chair  
Department of Endodontics  
University of the Pacific  
Arthur A. Dugoni School of Dentistry

Hans-Goran Grondahl, DDS, PhD (Odont Dr)  
Professor emeritus  
Department of Oral and Maxillofacial Radiology  
Institute of Odontology  
The Sahlgrenska Academy  
Gothenburg University, Gothenburg, Sweden

Dr. Richard S. Kahan  
Director of Endodontic Courses  
Honorary Clinical Lecturer  
Eastman CPD  
University College London (UCL)

Marcel Noujeim, DDS, MS  
Oral and Maxillofacial Radiology  
University of Texas Health Science Center at San Antonio

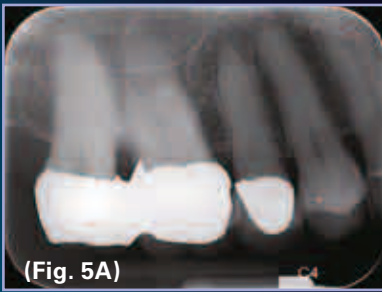Erkki Tammissalo  
Emeritus professor of Oral Radiology  
Tomodent, Private Laboratory of Oral Diagnostic Imaging  
Turku, Finland

Sotirios Tetradis, DDS, PhD  
Professor and Chair  
Section of Oral and Maxillofacial Radiology  
UCLA School of Dentistry

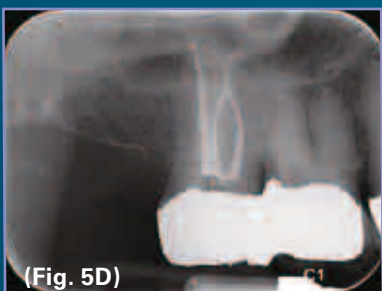
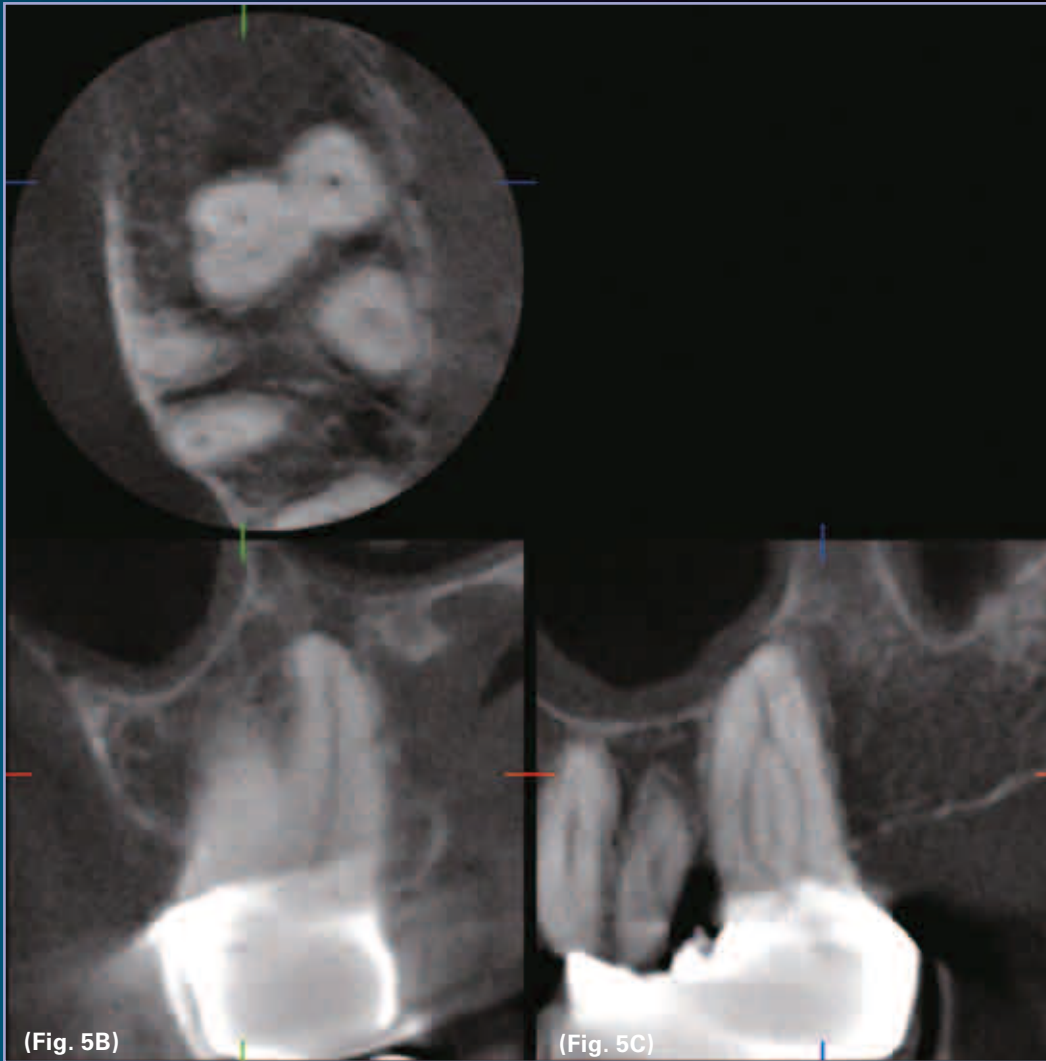Mitsuhiro Tsukiboshi, DDS, PhD  
Private Practice, Tsukiboshi Dental Clinic, Aichi, Japan



## ENDODONTICS CASE 1



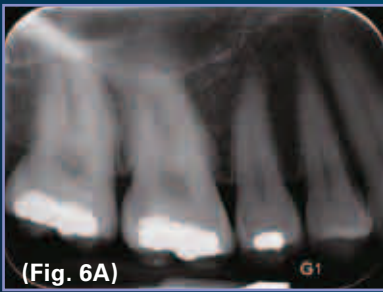The patient presented below suffered from an irreversibly inflamed pulp in tooth #2, confirmed by prolonged thermal responses to cold and heat. Conventional radiographs revealed a fused root structure with little or no information about the root canal anatomy (Fig. 5A).



Accutomo imaging revealed that this molar had only three canals (reassuring), and that the two buccal canals merged in the apical third and bifurcated again (Figs. 5B & C). The post-operative conventional radiograph shows this anatomy treated out, with pre-informed anatomic knowledge (no looking for a fourth canal, knowing that the buccal canal merge apically—very unusual—and with adequate time committed to the irrigation process that allowed a three-dimensional obturation of the apical bifurcation of the canal system after the confluence (Fig. 5D).

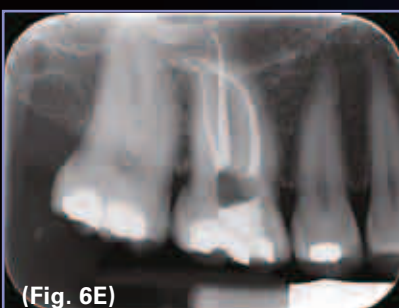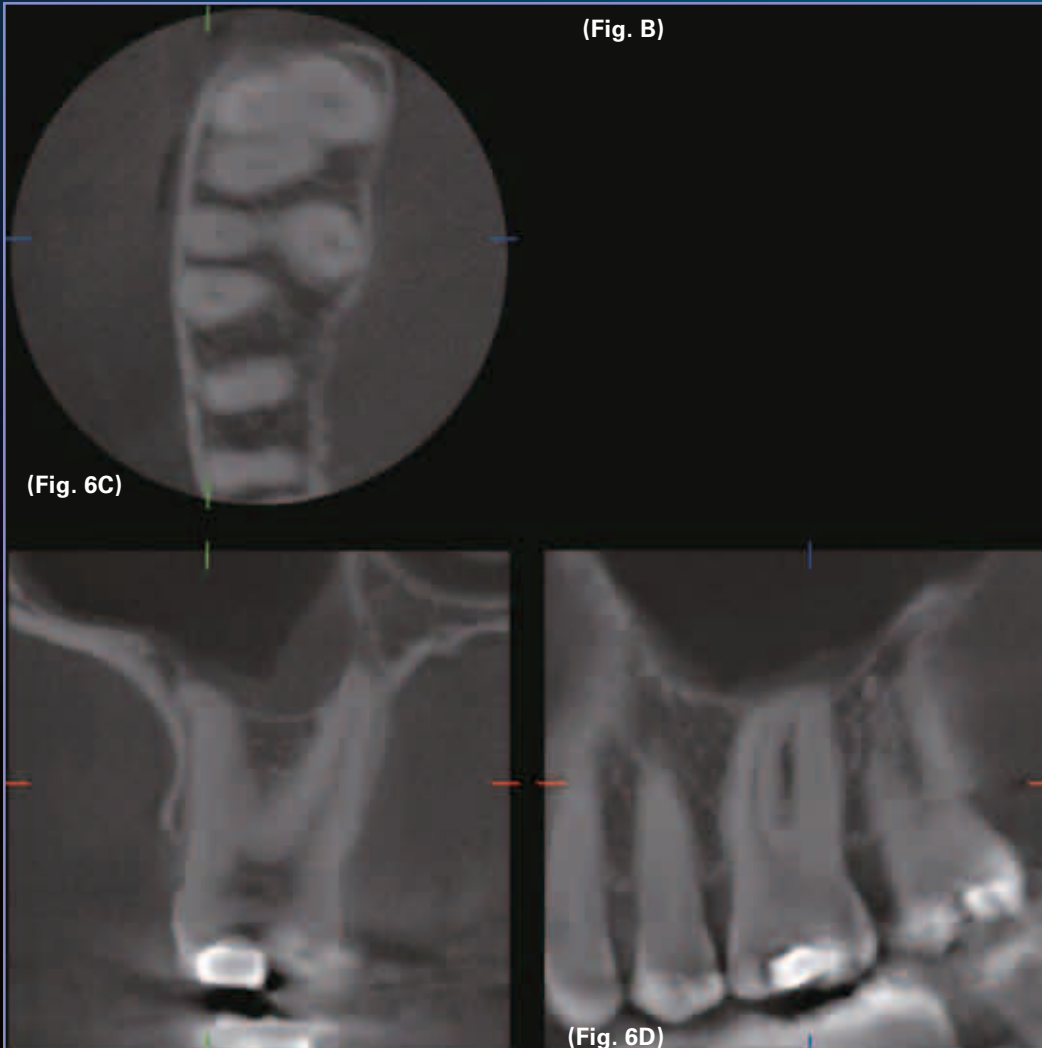
*-The case in this page was provided by Dr. L. Stephen Buchanan taken with the 3D Accutomo.*

## ENDODONTICS CASE 2



The patient presented with an irreversibly inflamed pulp in tooth # 3, confirmed by cold and heat testing (prolonged responses). Conventional radiographs revealed mesio-buccal root anatomy that was very curved, with the disto-buccal and palatal root anatomy appearing fairly straight (Fig. 6A).

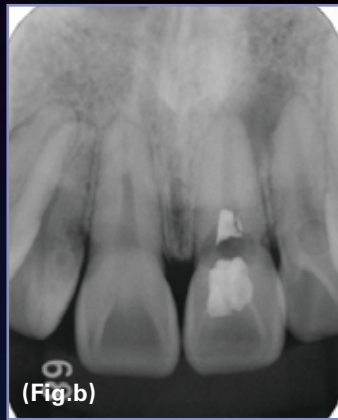
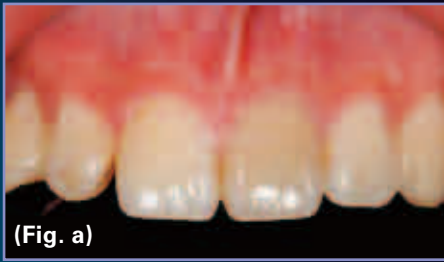Accutomo CT imaging revealed a different story, allowing me to tread carefully during treatment (Figs. 6B.). The first bit of important information was that this tooth unusually had only three canals (Fig. 6C).



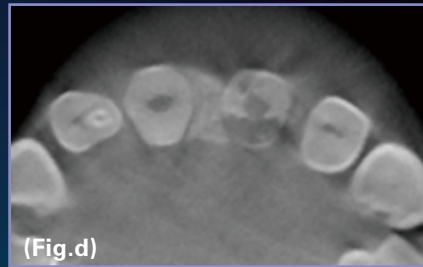
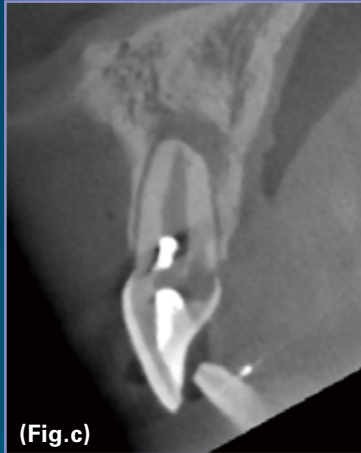The second piece of very important information was that the curvature of the mesiobuccal canal was truly awe-inspiring (Fig. 6D). The third piece of information saved my self respect and the patient's tooth from a broken rotary file, it revealed a severe canal curvature—in the normally-hidden buccal plane (Fig. 6E),. Treatment, as a result was quick and sure with an exceptional (sorry, but it's true) result (Fig. 6E).

*-The case in this page was provided by Dr. L. Stephen Buchanan taken with the 3D Accutomo.*

## ENDODONTICS CASE 3

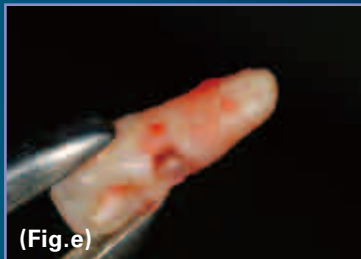

a. b. The first examination. A 20 year old male. The chief complaint was the discoloration of the crown of #9 and slight pain. External resorption from the palatal aspect and LEO were found. He has an experience of subluxation of the involved tooth 3 years ago.



c. d. CBCT appearances. c: sagittal. d: axial. The root resorption start from the cervical area on the palatal aspect and invaded into the dentin.

e. The extracted #9 for the surgical extrusion. Note the large lacuna on the palatal aspect.



f. The trimmed #9. 2-3mm of the apex was cut off and the apical foramen was retro-filled with light curing GIC. The crown portion was cut off obliquely.

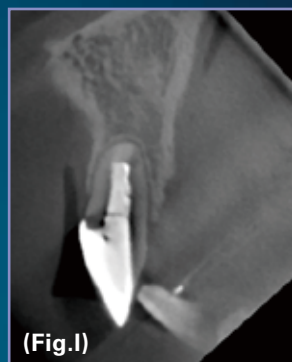
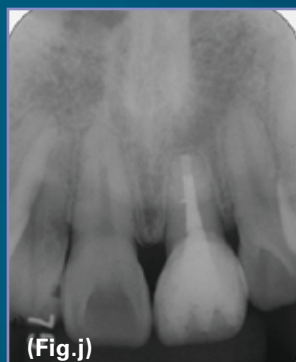
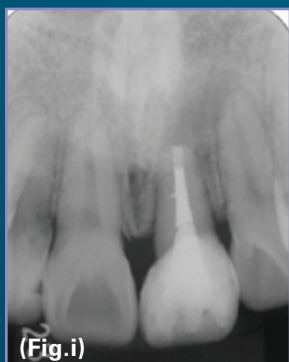
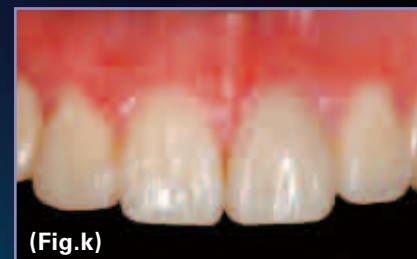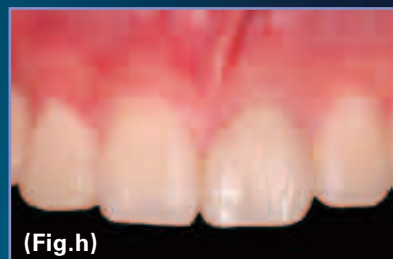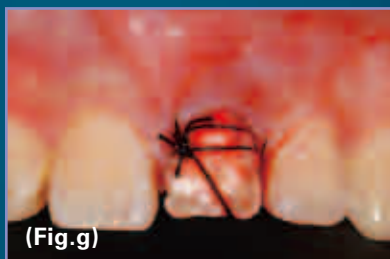g. Just after the surgical extrusion. The root was rotated 180 degree. The fixation was only with the suture strings. Surgical dressing was applied for the first two days and the suture was removed 4 days after the surgery. No other splinting was performed any longer.

h. 3 weeks after the surgical extrusion and just after the restoration of the crown with composite in a direct method.

i. A radiograph two months after the surgery.

j. A radiograph 1 year post op.

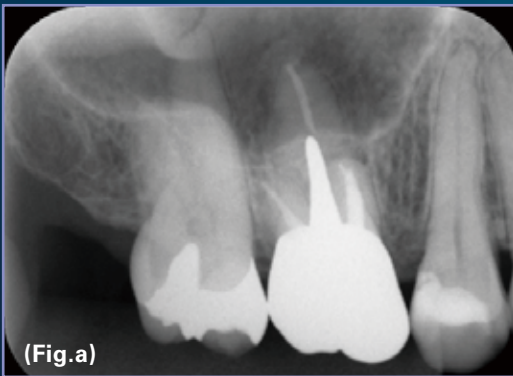
k. A clinical appearance 1 year post op.



l. CBCT appearance 1 y. post op. The PDL space and the buccal alveolar bone is nicely preserved. No resorption is observed. Interesting is that the PDL is formed over the retro-filling materials.

-The case in this page was provided by Dr. Tsukiboshi taken with the 3D Accutomo.

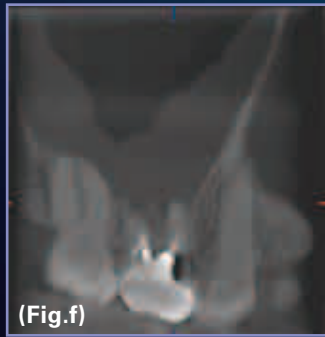

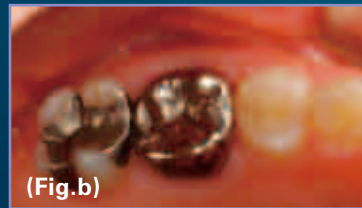
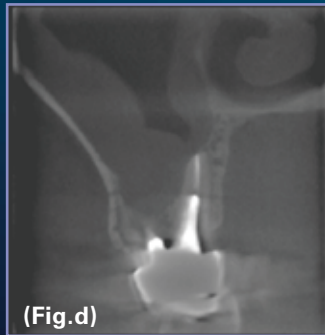

# ENDODONTICS CASE 4



a. ~f. Before treatment. A 46 year old female. The chief complaint is pain around #3.

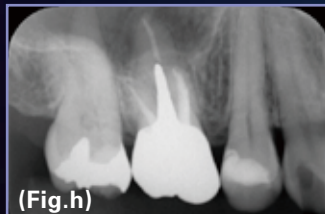The bone of the sinus floor is badly resorbed and the Schneiderian membrane is thickened due to inflammation. The cause was considered to be the inappropriate canal treatment of the mesial root.

- a: Periapical radiograph
- b: Clinical view
- c: Coronal view of the mesial root
- d: Coronal view of the palatal root
- e: Coronal view of the distal root
- f: Sagittal view of the mesial and distal roots

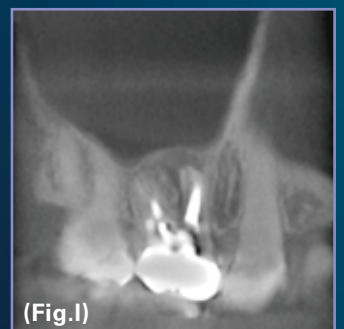
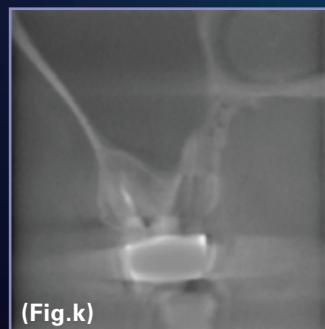
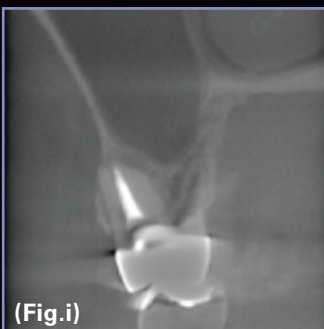


g. During treatment. Only the mesial root was retreated endodontically using a microscope.

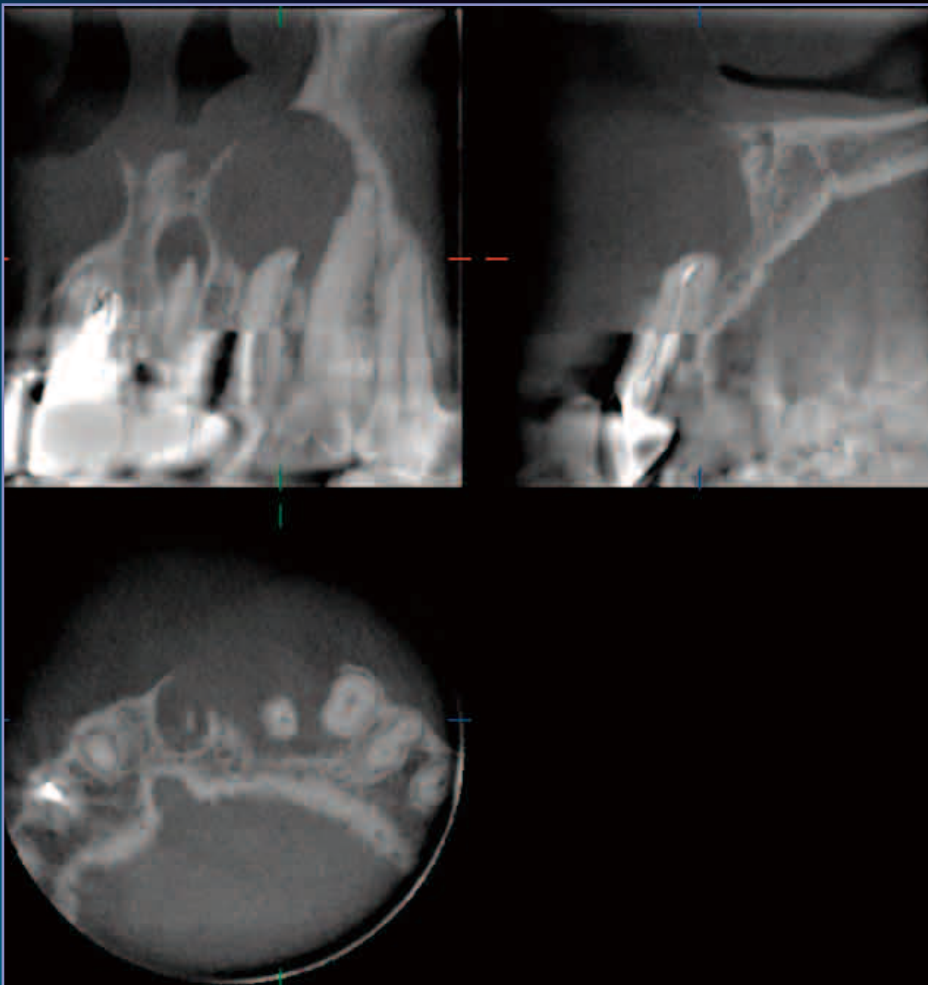
h. Periapical radiograph six months later.



i ~ l: CBCT appearance six months later. The sinus bone has come back and the Schneiderian membrane looks normal.



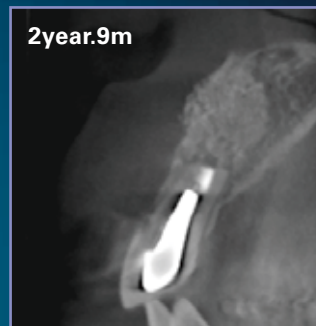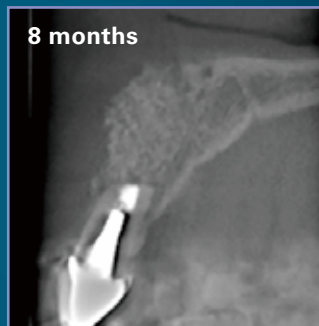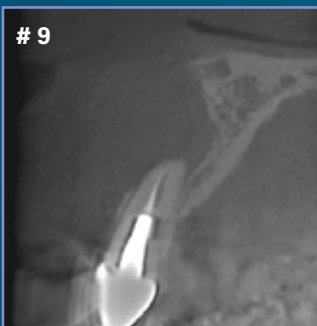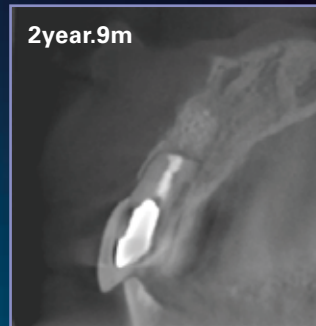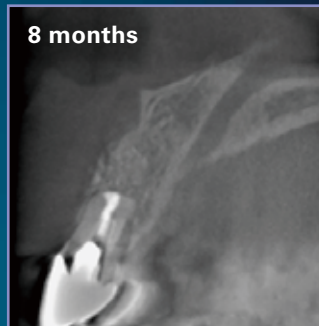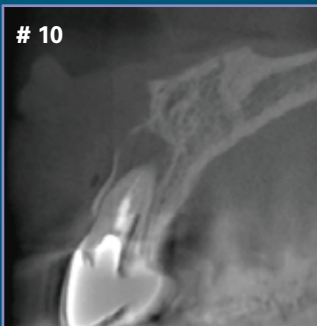## ENDODONTICS CASE 5



**Apicoectomy and follow-up with CBCT**

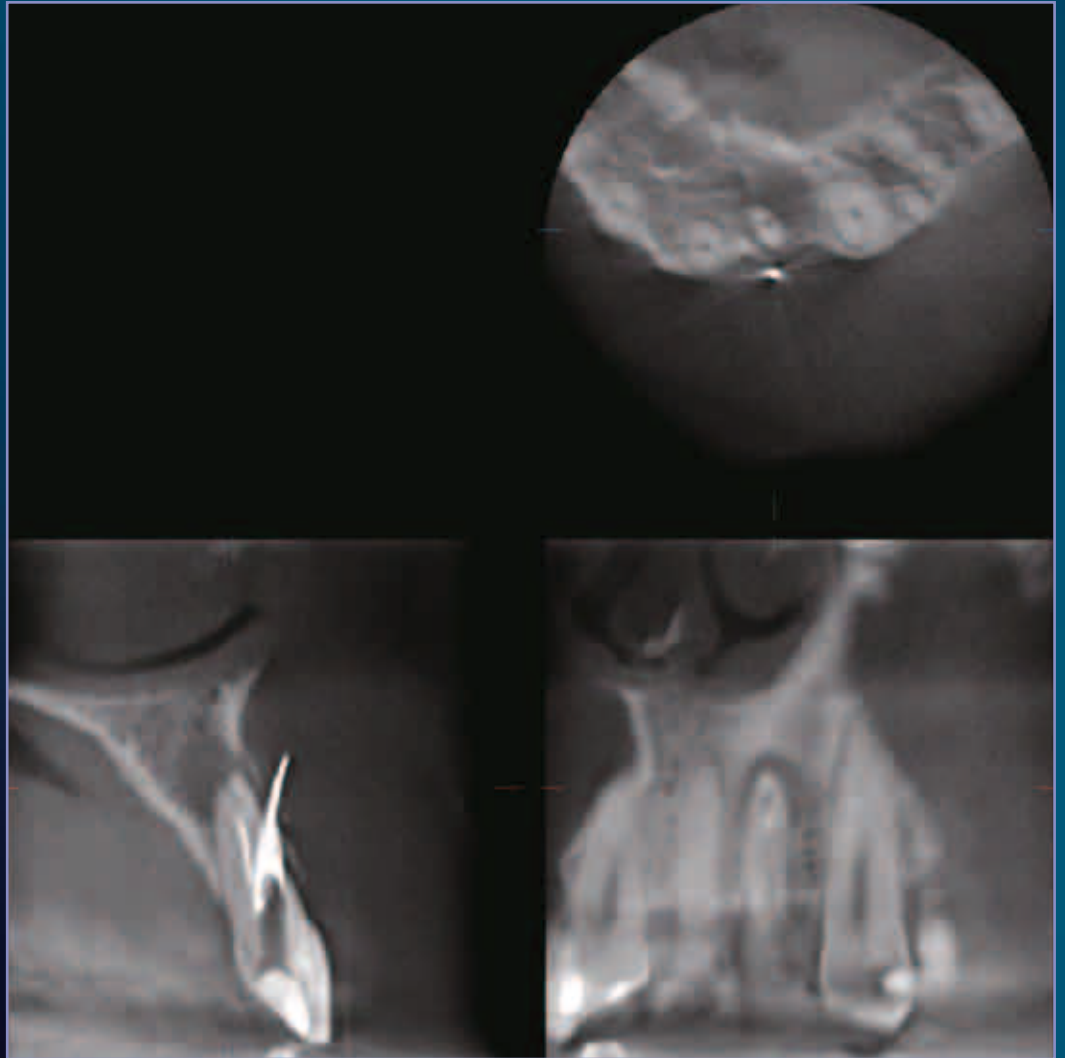
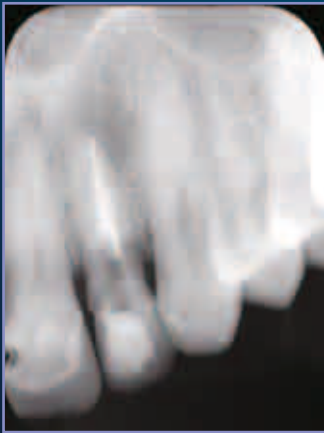**A 41 year old female. #9 and #10 suffer LEO and apicoectomy was indicated.**

**3mm of each apex was cut off and the bony defect was filled with Bio-oss after the retro-fillings. The healing of the involved teeth was followed up with CBCT.**



*-The case in this page was provided by Dr.Tsukiboshi taken with the 3D Accuitomo.*

## ENDODONTICS CASE 6



The periapical and panoramic radiographs show an “acceptable” endodontic treatment reaching the slightly lateral apex of tooth # 10. The endodontic filling lateral appears to be “doubled”, giving the impression of the presence of two canals. Ill-defined periapical radiolucency is noted slightly on the distal aspect of the apical third.

Cone beam images show that the gutta percha is perforating the facial aspect of the root and the buccal cortex. Some gutta perch is found in the canal but it is not reaching the apex.

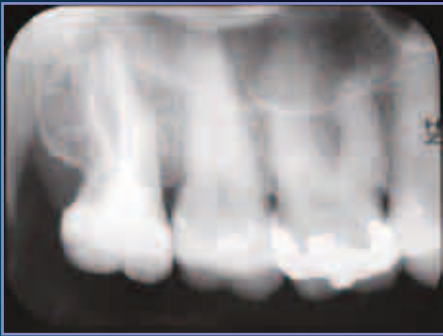Periapical radiograph is a 2d presentation of a 3d object; it collapses all the structures in the examined area in one plane. The image of the gutta percha is projected over the image of the root giving the impression of an acceptable treatment.



*-The case in this page was provided by Marcel Noujeim DDS MS taken with the 3D Accuitomo.*

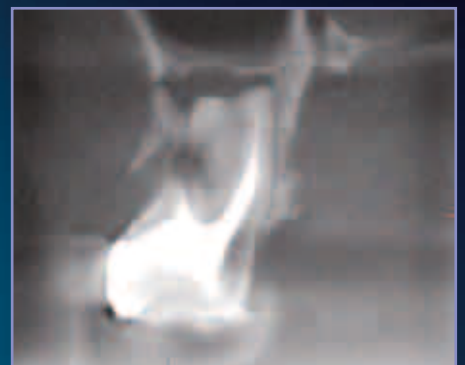
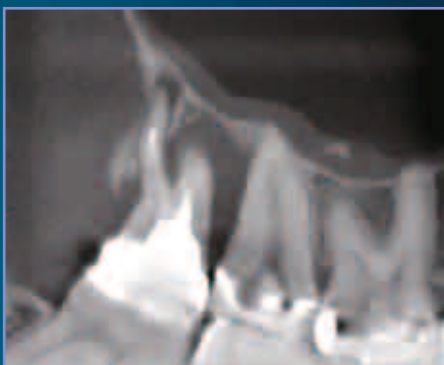
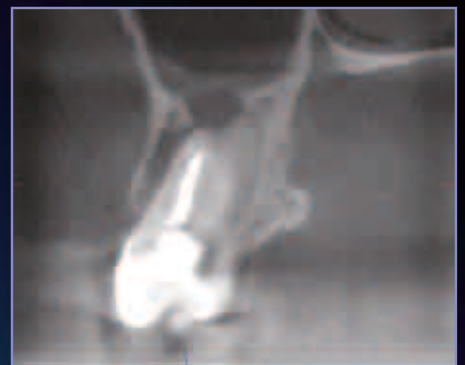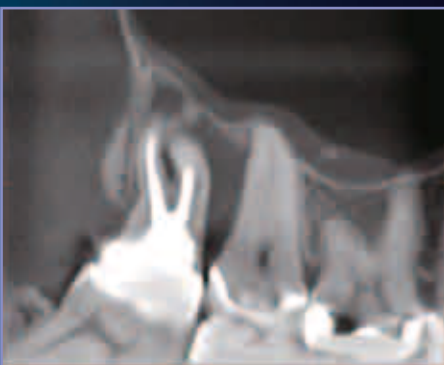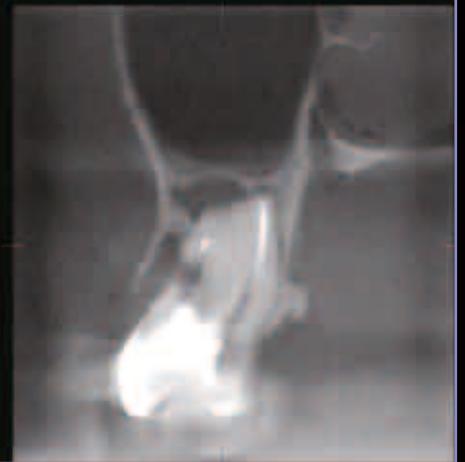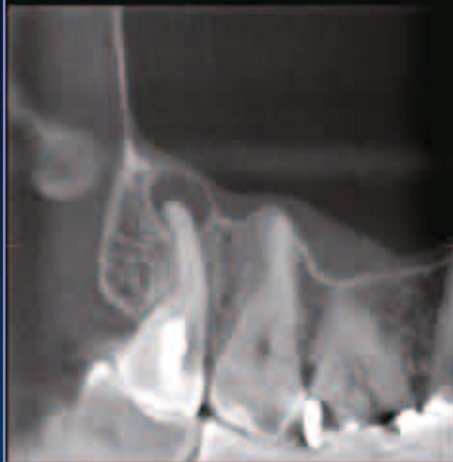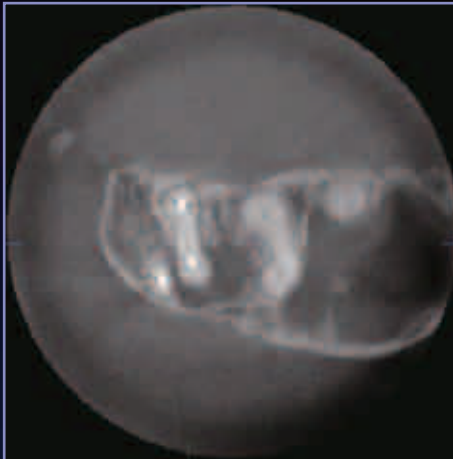## ENDODONTICS CASE 7



The periapical radiograph shows a well corticated, 3-4mm periapical radiolucency onto the second molar. The tooth is endodontically treated and the endodontic filling material is homogenous, well condensed, and reaching the apex.

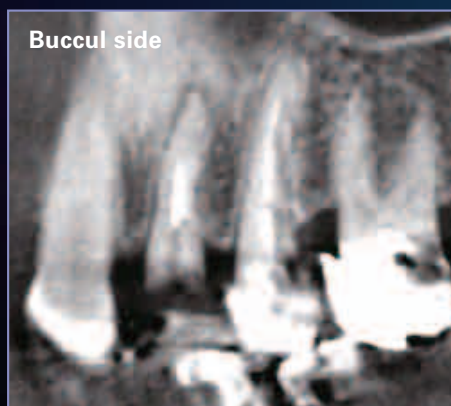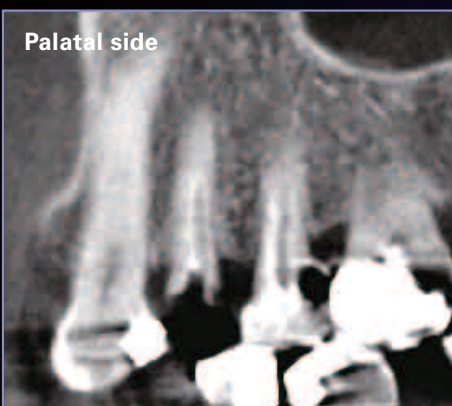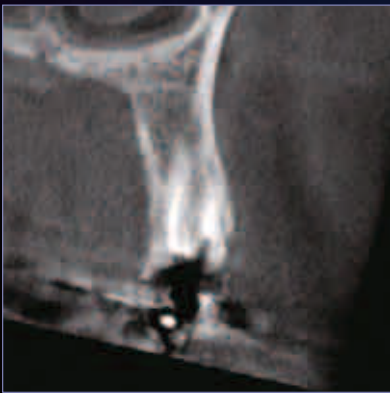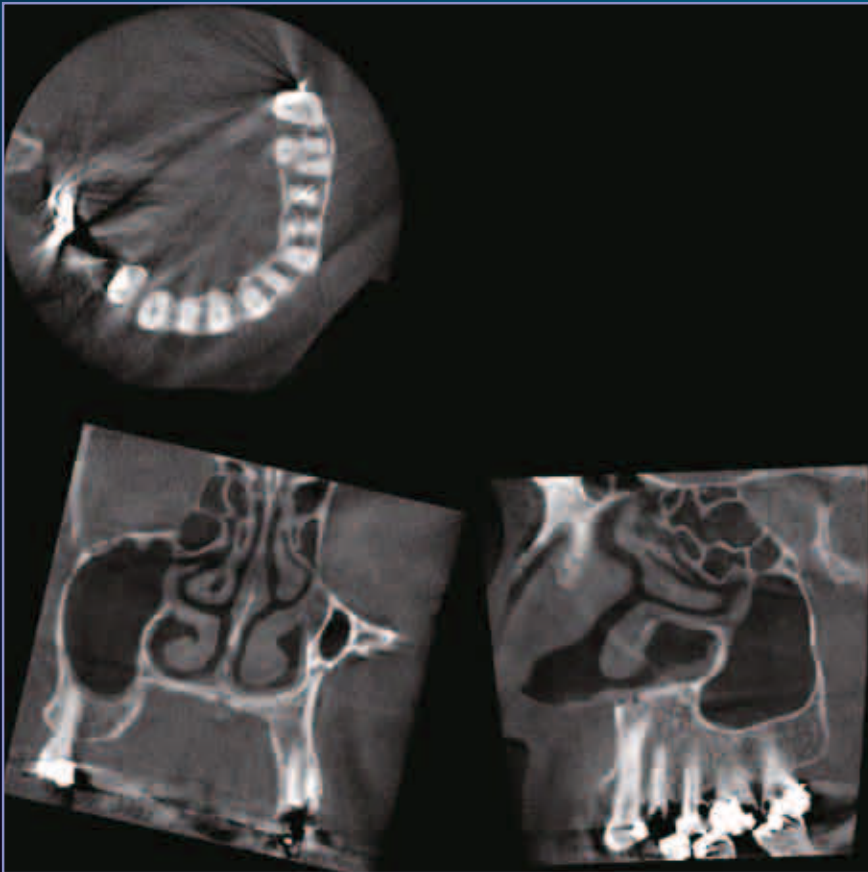
On the cone beam CT, the periapical lesion presence is confirmed with the presence of a severe vertical periodontal bone loss reaching the apex of the tooth in the form of what we call "endo-perio" communication. This finding was not seen on the periapical film due to the projection of the buccal and palatal thick cortical bones over the image of the periodontal lesion.



-The case in this page was provided by Marcel Noujeim DDS MS taken with the 3D Accutomo.

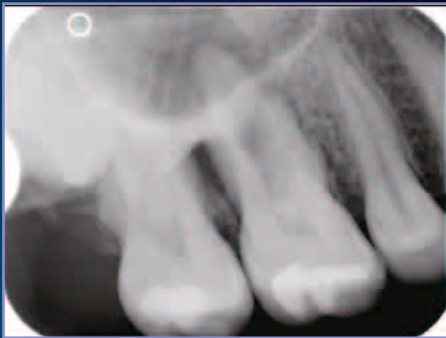## ENDODONTICS CASE 8

The patient was complaining of diffuse pain over the left maxilla. Conventional radiographs did not reveal pathological changes in the periapical region of premolars and molars. A Veraviewepocs 3D scan shows an air-filled, healthy, maxillary sinus and a periapical lesion at the apex of the buccal root of the first premolar.



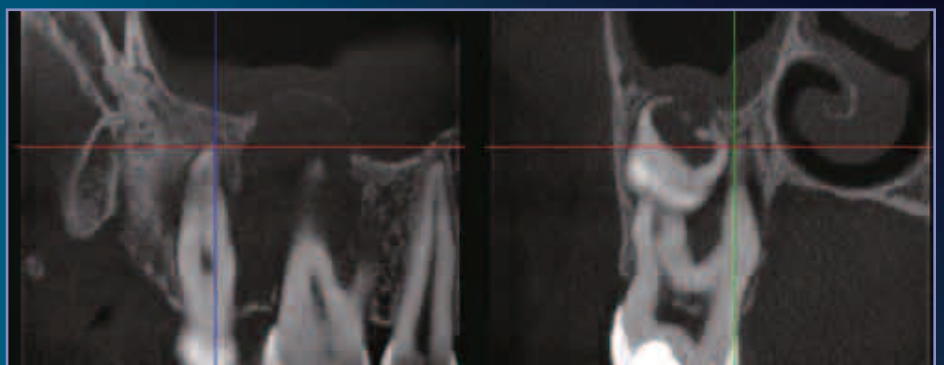
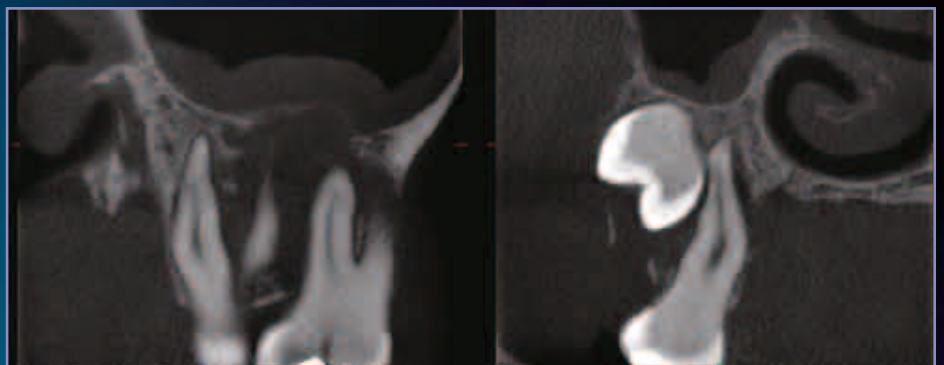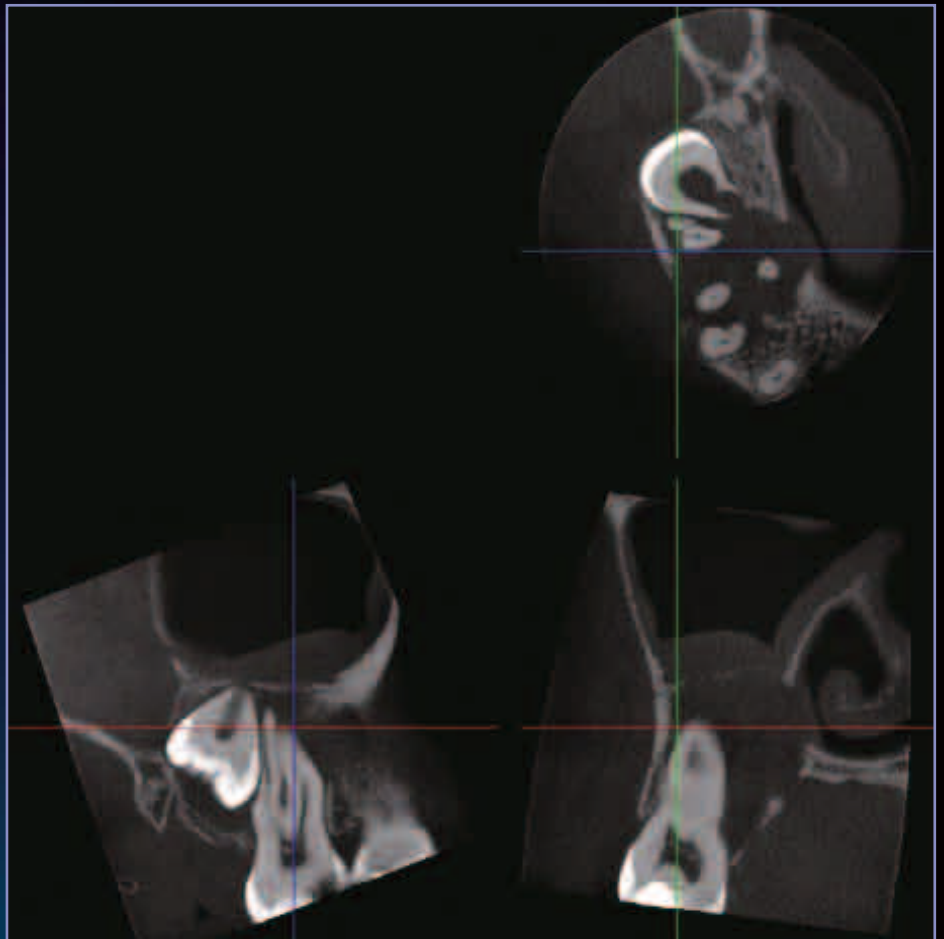
*-The case in this page was provided by Dr. Erkki Tammissalo taken with the Veraviewepocs 3D.*

## ENDODONTICS CASE 9



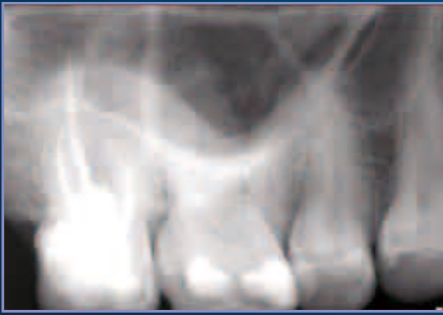An endodontist had taken several images of the upper right molar region on a patient who presented with pain. He could see that a lesion was present at the first molar, but was uncertain about its extent.

The Accutomo images showed a lesion with a very large extent in all directions. It has caused a break-down of both the buccal and palatal cortical borders. It extends into the lateral part of the nasal cavity and the lower part of the maxillary sinus where a reaction is seen in the mucosa. The lesion also involves the root system of the second molar and gets very close to the unerupted third molar. None of this could be anticipated from intra-oral radiographs alone.

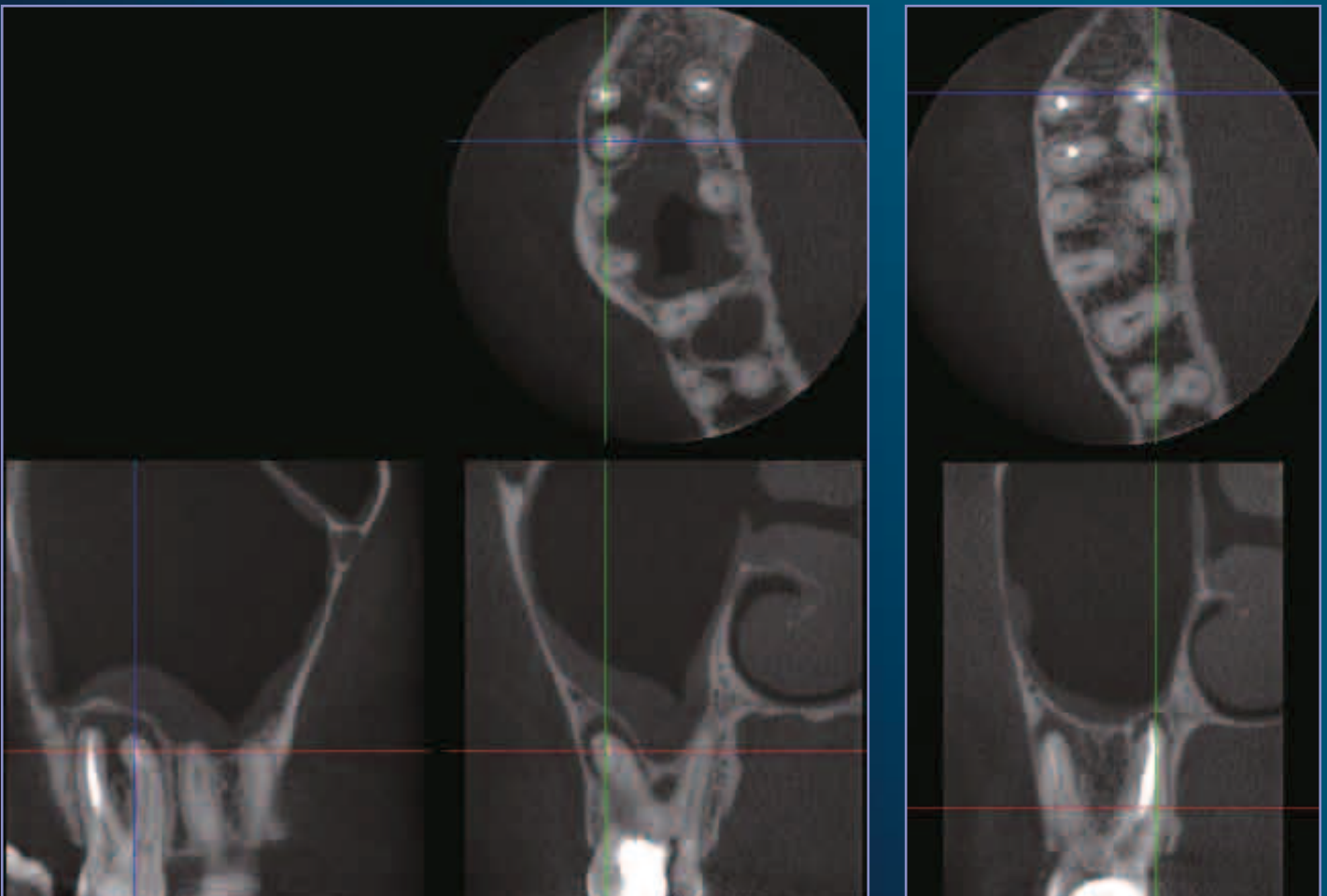


-The case in this page was provided by Hans-Göran Gröndahl Professor emeritus, DDS, PhD taken with the 3D Accutomo.

## ENDODONTICS CASE 10



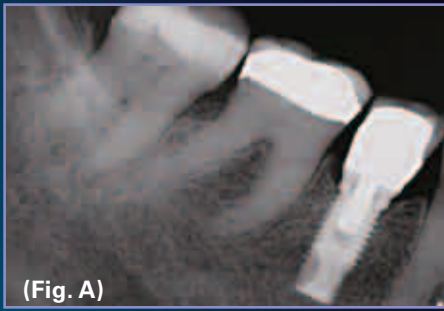Although having taken several intraoral radiographs, an endodontist still felt uncertain about the conditions at the upper right second molar from which the patient still felt some pain after an endodontic treatment had been completed.



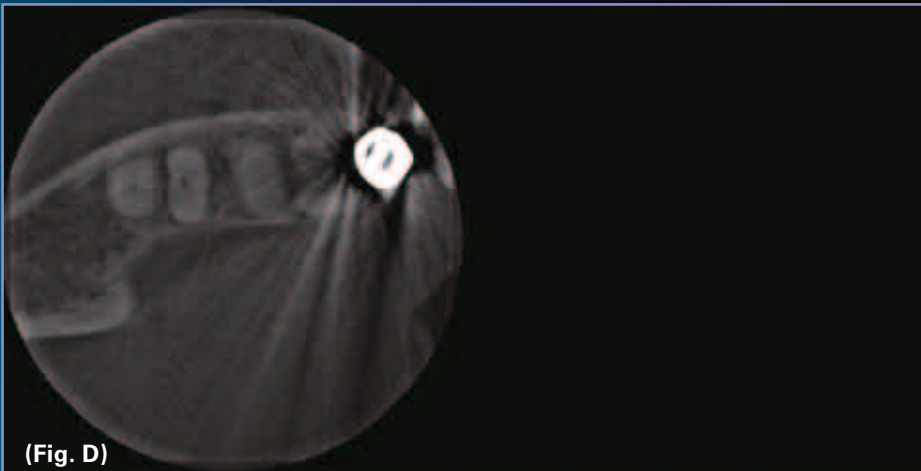
The Accuitomo images show lesions at the two buccal roots and at a palatal root, but also that a second palatal root exists in which the root canal has not been treated. In addition, a lesion is seen in the interradicular area between the latter and the mesiobuccal root. The lesion at the buccal roots extends into the lower part of the maxillary sinus in which a thickening of the mucosa can be seen.

*-The case in this page was provided by Hans-Göran Gröndahl Professor emeritus, DDS, PhD taken with the 3D Accuitomo.*

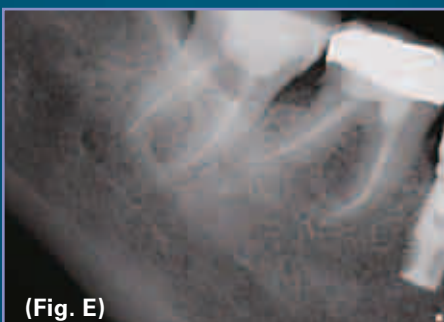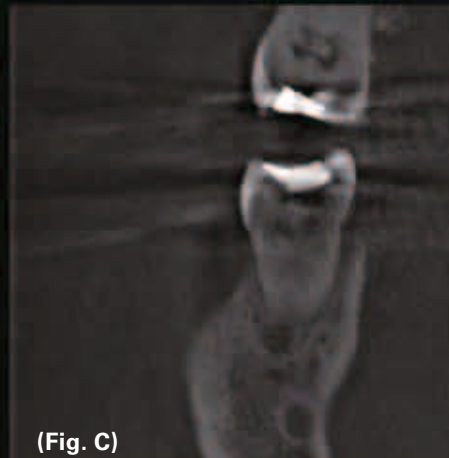
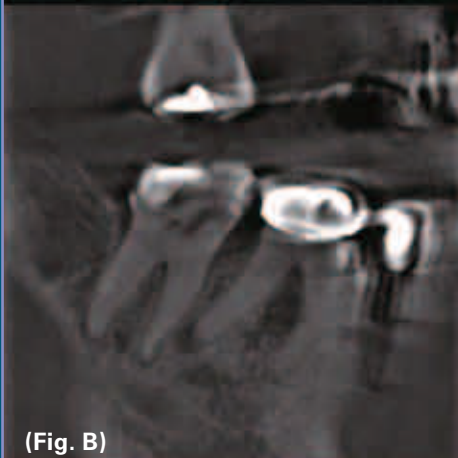## ENDODONTICS CASE 11



Clinical examination of the LR5, LR6 and LR7, revealed no abnormalities with no tenderness to palpation at the buccal and lingual root apices and no tenderness to percussion of any of the teeth. Vitality testing could not be carried out at the LR6 as the crown margin was subgingival. The LR7 predictably did not respond to the electric pulp test. The periapical radiograph (Fig. A ) revealed widening at the periapex of the LR7 with no other signs of pathology.

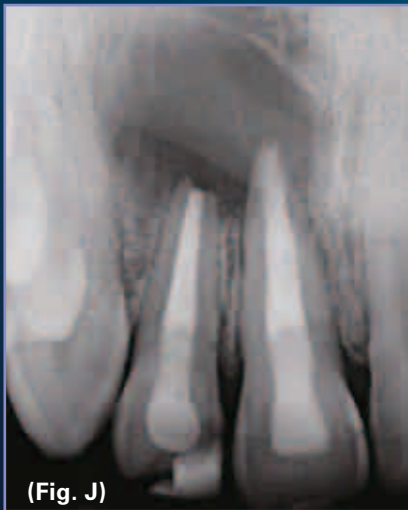

The sagittal slices of the microCT scan (Fig. B) however clearly showed a 4mm circular lesion associated with the apex of the distal root of the LR7. The reason why this could not be seen on the periapical radiograph could be understood from the coronal slice (Fig. C) that shows the lesion positioned entirely in cancellous bone and not involving the cortical plates – the prerequisite for visibility on a standard periapical radiograph. Furthermore the anatomy of the root canals in the LR7 could be visualized with there being clearly one mesial and one distal canal (Fig. D).

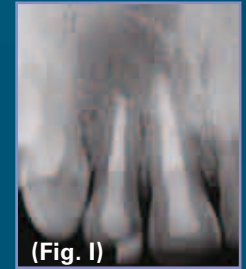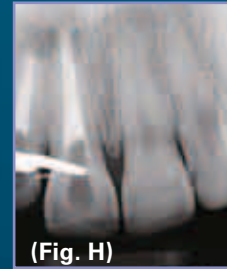

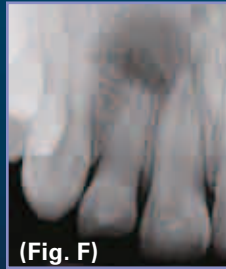


Without the microCT scan provided by the Veraviewepocs 3D, an attempt would have been made to find another canal in the LR7, as there was no reason to treat the LR6. Significant damage to the root of the tooth would have occurred before the search would have been abandoned, and the patient would still have been in pain following the procedure. With the scan, treatment was initiated immediately in the LR6 and the pain quickly eased. Endodontic treatment of the LR7 when completed, was done without further damage in an attempt to locate a second mesial canal (Fig. E).

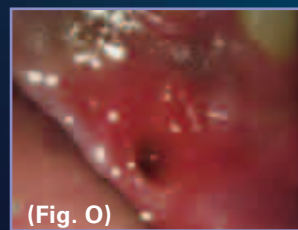
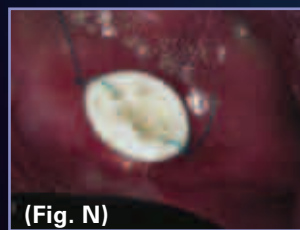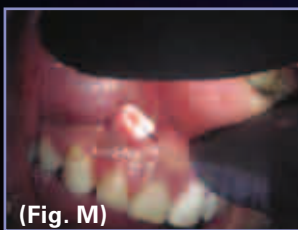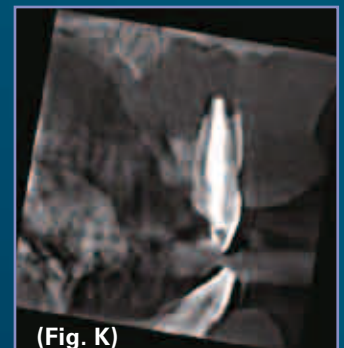## ENDODONTICS CASE 12



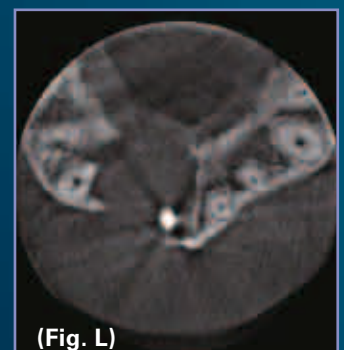A 24 year old male patient attended 2 years following root canal therapy of his upper right central and lateral incisors (UR1 and UR2) with a draining buccal fistula (Fig. J). The teeth had been originally traumatised aged 10 and the apices were incompletely formed. On presentation with periapical infection aged 22 (Fig. F), the orthograde root canal treatments that were carried out had initially involved calcium hydroxide therapy followed by obturation with MTA apical plugs (Figs. G & H). Initial follow up at 6 months suggested some resolution (Fig. I), but the appearance of a fistula 18 months later confirmed regression and re-infection.



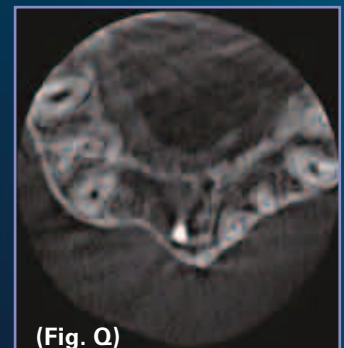
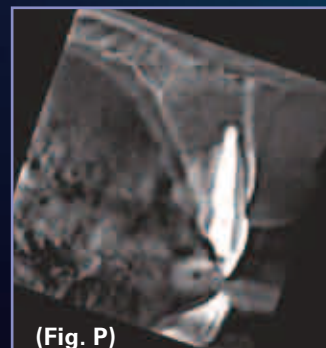A microCT scan of the lesion using the Veraviewepocs 3D (Figs. K & L) revealed the true size of the lesion with both buccal and palatal plate perforations. The usual treatment of a recurrent periapical lesion with a satisfactory orthograde root filling would be buccal approaching periapical surgery with lesion curettage, apicectomy and possibly an apical retrograde seal. However, if this would have been carried out with such a lesion, soft tissue ingrowth from the palatal side would resist bony repair. True repair of a lesion of this size would require either a membrane on one side of the lesion to resist soft tissue ingrowth, or decompression followed by conventional surgery. Whichever is chosen, neither would have been immediately considered in a case such as this, and therefore, poor bone healing would have followed on from a standard surgical approach without the benefit of the microCT scan.



In this case a decompression procedure was carried out and a plastic drain was placed buccally (Fig. M & N) with the patient instructed to irrigate the underlying bony cavity with Corsodyl using a syringe. The drain stayed in place for 2 weeks and was then removed (Fig. O).

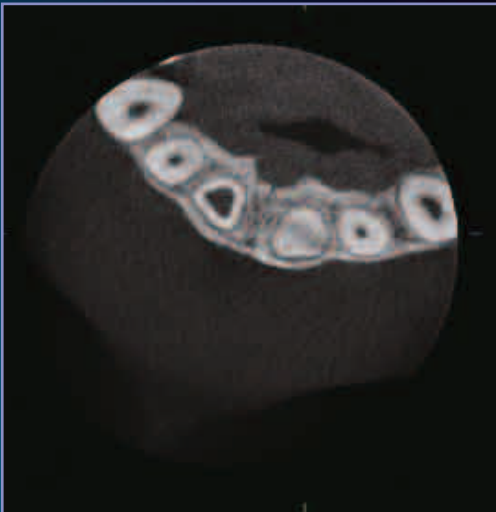


A microCT scan carried out after 6 months showed shrinkage of the lesion and full reformation of both buccal and palatal plates (Figs. P & Q). Although buccal approaching periapical surgery with lesion curettage and apicectomy was now possible, with the lesion asymptomatic and good healing it was decided to leave and observe further on the basis that marsupialisation of a true cyst might have occurred and contamination at the root apices were no longer an issue. A further review was scheduled for 1 year.



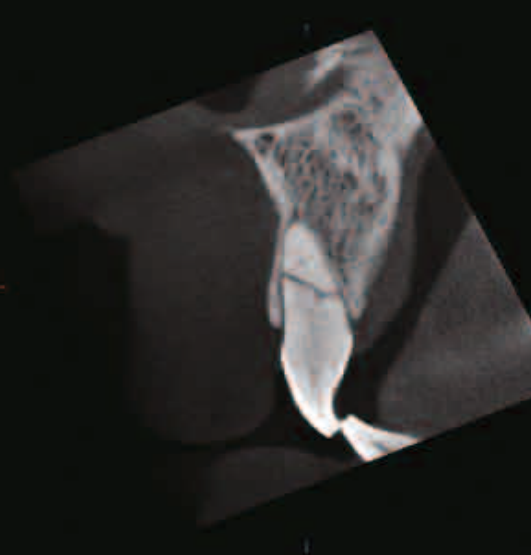
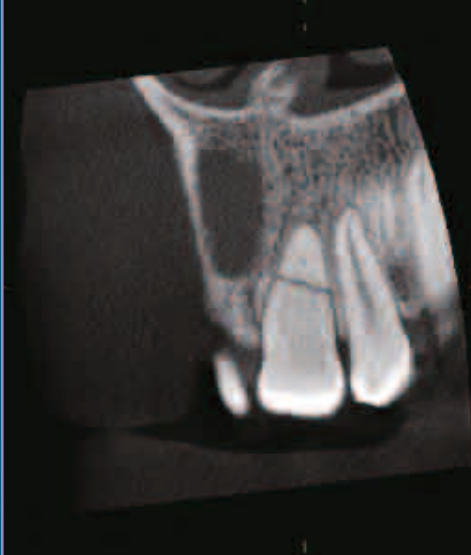*-The case in this page was provided by Dr. Richard S. Kahan taken with the Veraviewepocs 3D.*

## TOOTH FRACTURE CASE 1



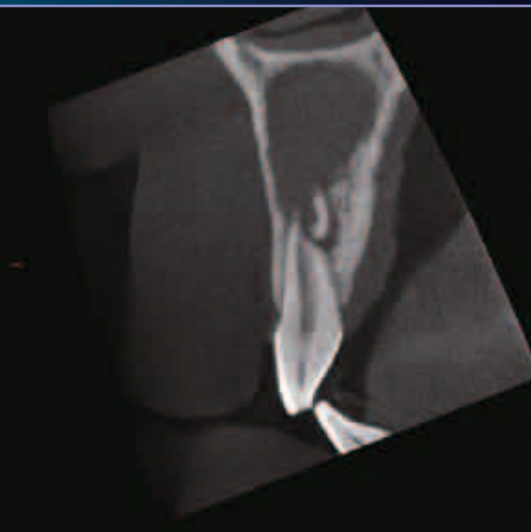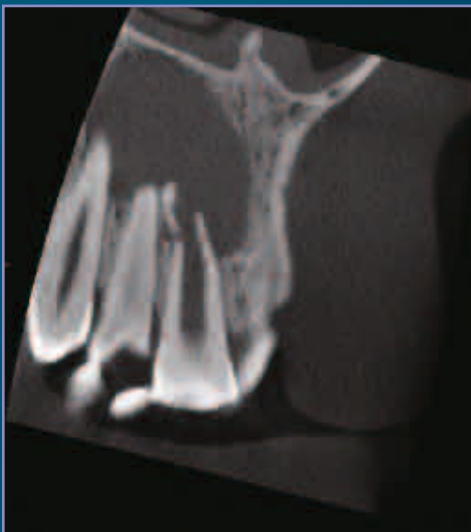
This patient presents with discolored upper medial incisors. Several years ago he had received a blow to his upper front teeth but had received no treatment. Lack of symptoms and dental resources made him forget about his teeth until a dentist in his new home country made him aware of the discoloration of his upper incisors. At a recent visit to the dentist he describes that he sometimes has a dull pain in the area of the upper right medial incisor.

An Accuitomo examination of the upper frontal region demonstrates an upper right medial incisor with a very wide root canal. This can be seen in teeth that have become devitalized at an early age. At the apex of this tooth, a large cystic lesion can be seen. Its borders are not clearly defined and the surrounding bone is denser than normal. The lesion, thus, has the appearance of an infected apical cyst.

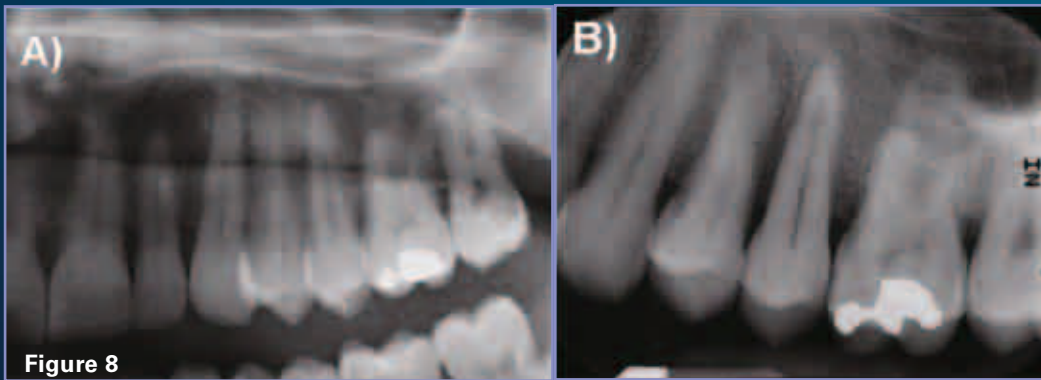


The examination also shows a fracture of the apical part of the right medial incisor.

In the left medial incisor, an almost horizontal root fracture is seen. In both the apical and the coronal fragments, the pulp is almost completely obliterated.

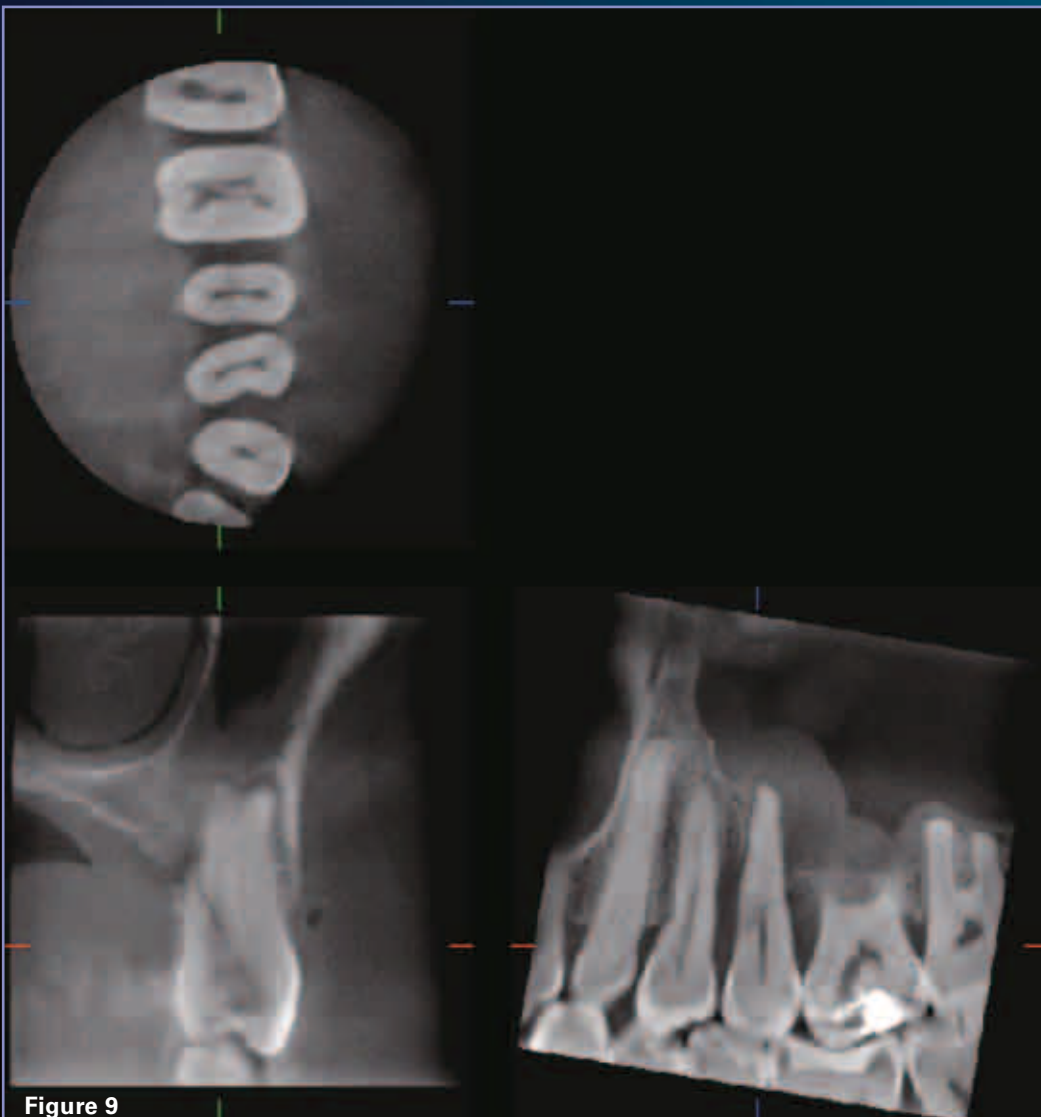

## TOOTH FRACTURE CASE 2



This 48 year old male patient complains of severe pain in the left maxilla that developed after eating. Panoramic (Fig. 8A) and periapical radiographs (Fig.8B) show a possible widening of the periodontal ligament space at the mesial surface of tooth #13. The Accuitomo scan (Fig. 9) clearly reveals an oblique fracture of the root of #13 that extends from the palatal surface of the root towards the buccal surface of the crown of #13. Interestingly, the fracture does not extend into the enamel, but appears to end at the area of the dento-enamel junction. There is also widening of the periodontal

ligament space along the fracture line. Finally, there is thickening of the mucoperiosteal lining of the floor of the left maxillary sinus consistent with maxillary sinusitis, that most probably is unrelated to the dental disease described above.



-The case in this page was provided by Dr. Sotirios Tetradis taken with the 3D Accuitomo.



## TOOTH FRACTURE CASE 3

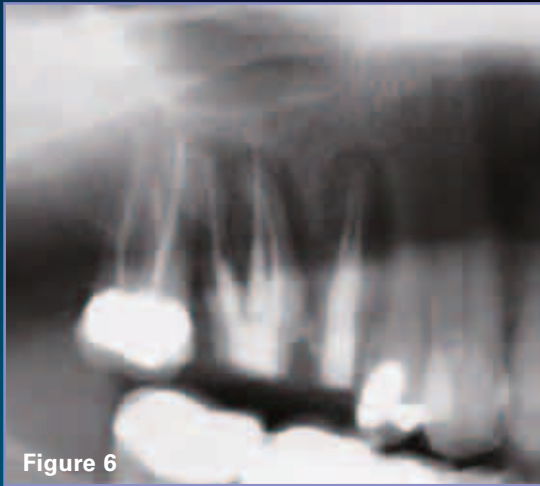


Figure 6

This 67 year old female patient underwent endodontic treatment of teeth #3 and 4, four weeks ago. Despite the apparent successful endodontic treatment, the patient reports severe pain in the area. A panoramic radiograph (Fig. 6) demonstrates widening of the periodontal ligament space around the apical area of all the roots of #3 and 4. However, Accuitomo scan reveals a longitudinal root fracture of the mesiobuccal root of #4 and extensive bone loss at the whole extent of the mesio-buccal root and destruction of the buccal cortex of the maxilla at the area (Fig.7).

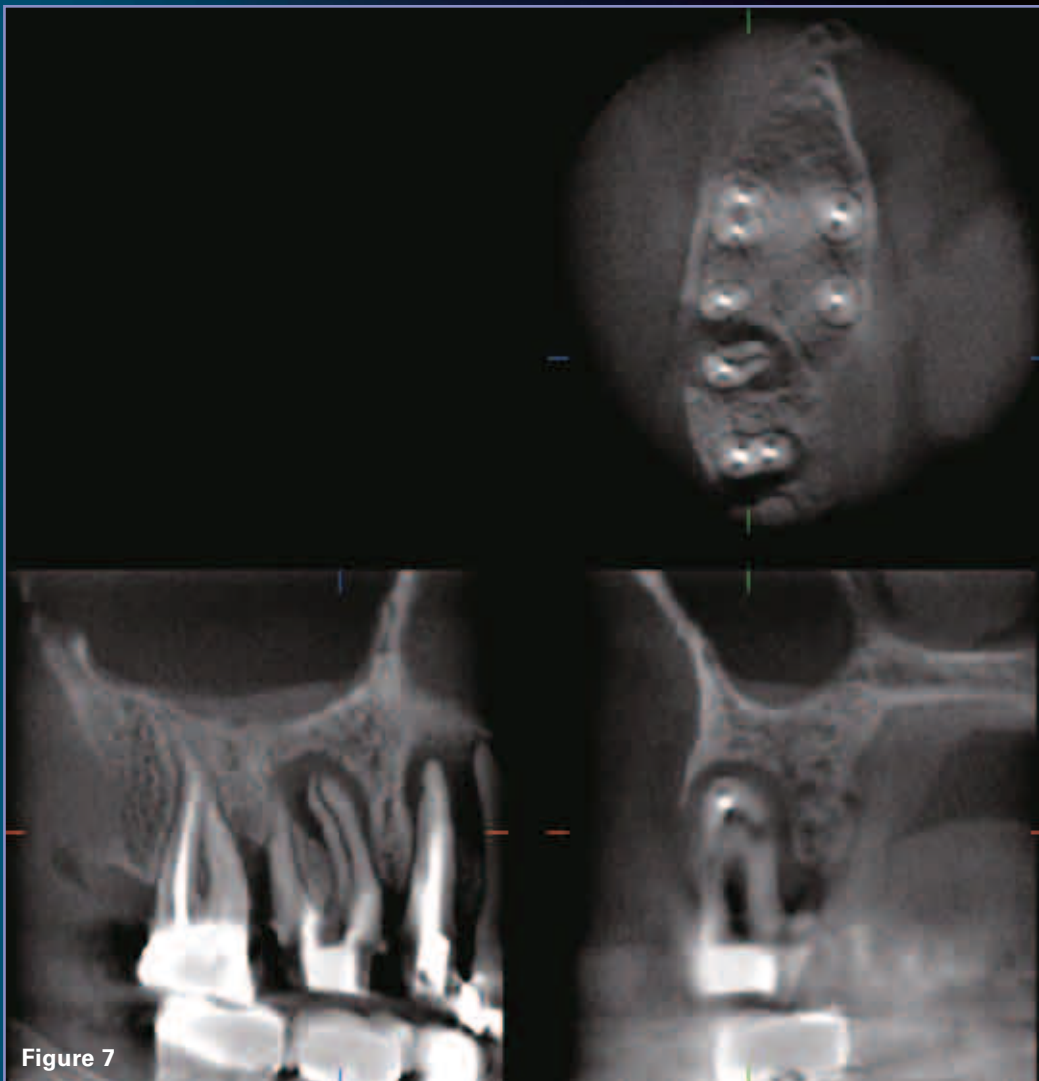


Figure 7

*-The case in this page was provided by Dr. Sotirios Tetradis taken with the 3D Accuitomo.*

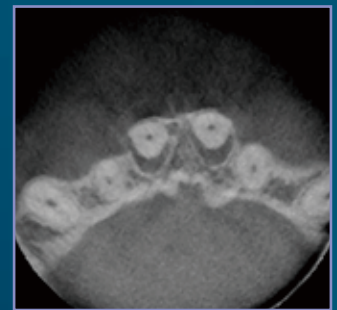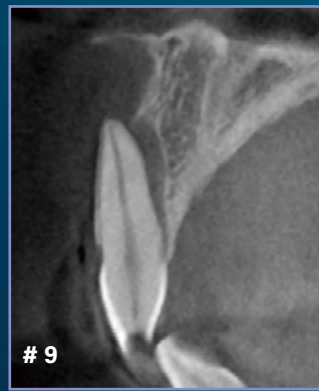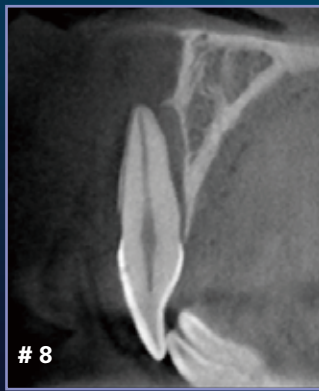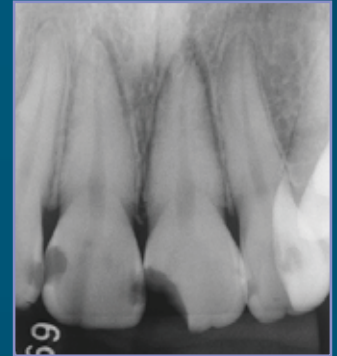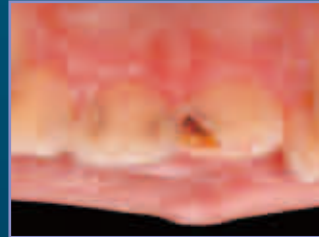
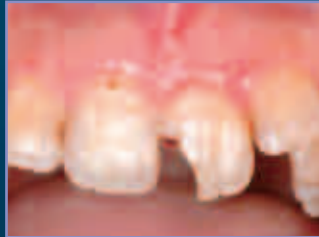# LATERAL LUXATION CASE 1

Lateral luxation and follow-up with CBCT.

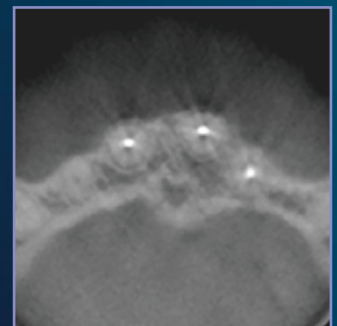
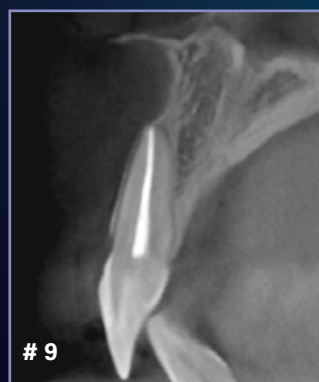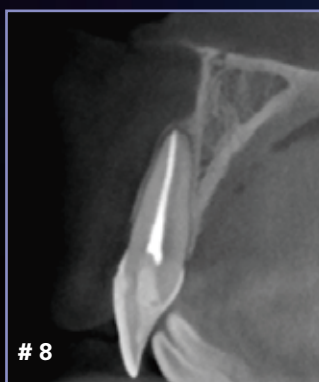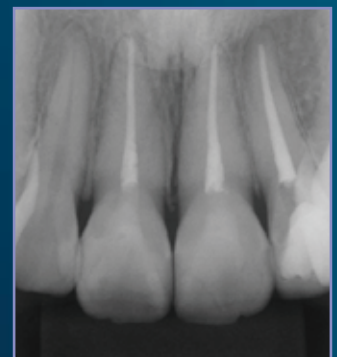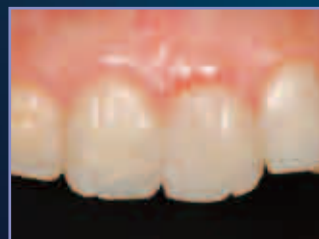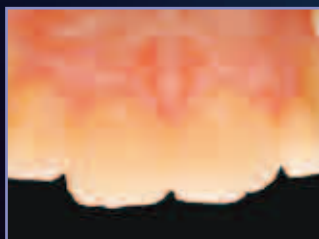A 23 year old female. Two central incisors are involved with lateral luxation, which is very difficult to diagnose with conventional methods, but is easily revealed with CBCT.

One year 3 months follow-up result with CBCT has shown the complete healing.

Before

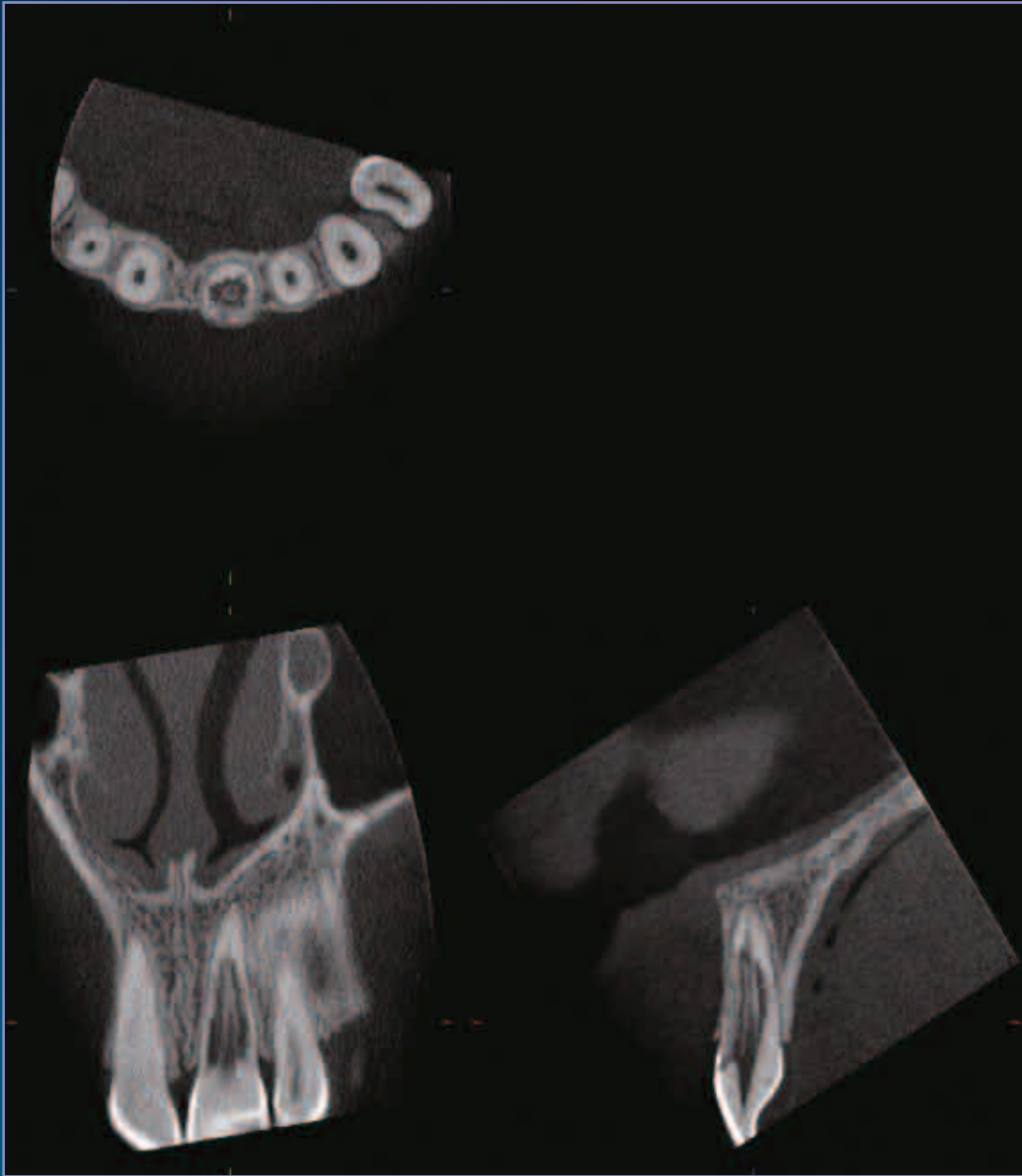

1 year and 3 months later<sup>1</sup>



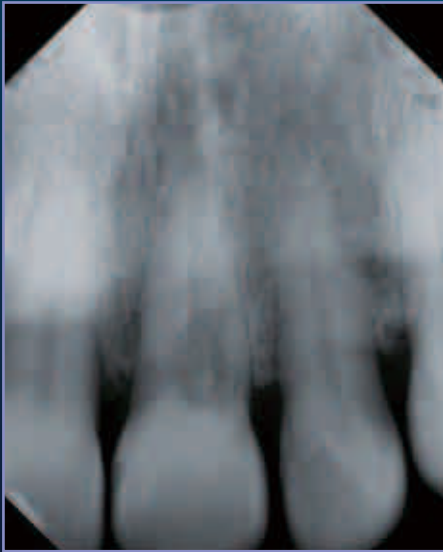
*-The case in this page was provided by Dr. Tsukiboshi taken with the 3D Accutomo.*

## INTERNAL RESORPTION CASE 1



In a symptomless patient with known trauma to her upper left medial incisor several years ago, the Accuitomo examination shows a severely resorbed tooth. The images demonstrate the clarity with which resorptions now can be studied. Note that the walls of the pulp still remain and that there is a lack of buccal bone at the middle of the root. In all likelihood, the origin of this resorption is external rather than internal.

## INTERNAL RESORPTION CASE 2



The first image is a traditional periapical film that shows the resorption superimposed over the pulpal space making it very difficult to determine the origin of the resorptive process.

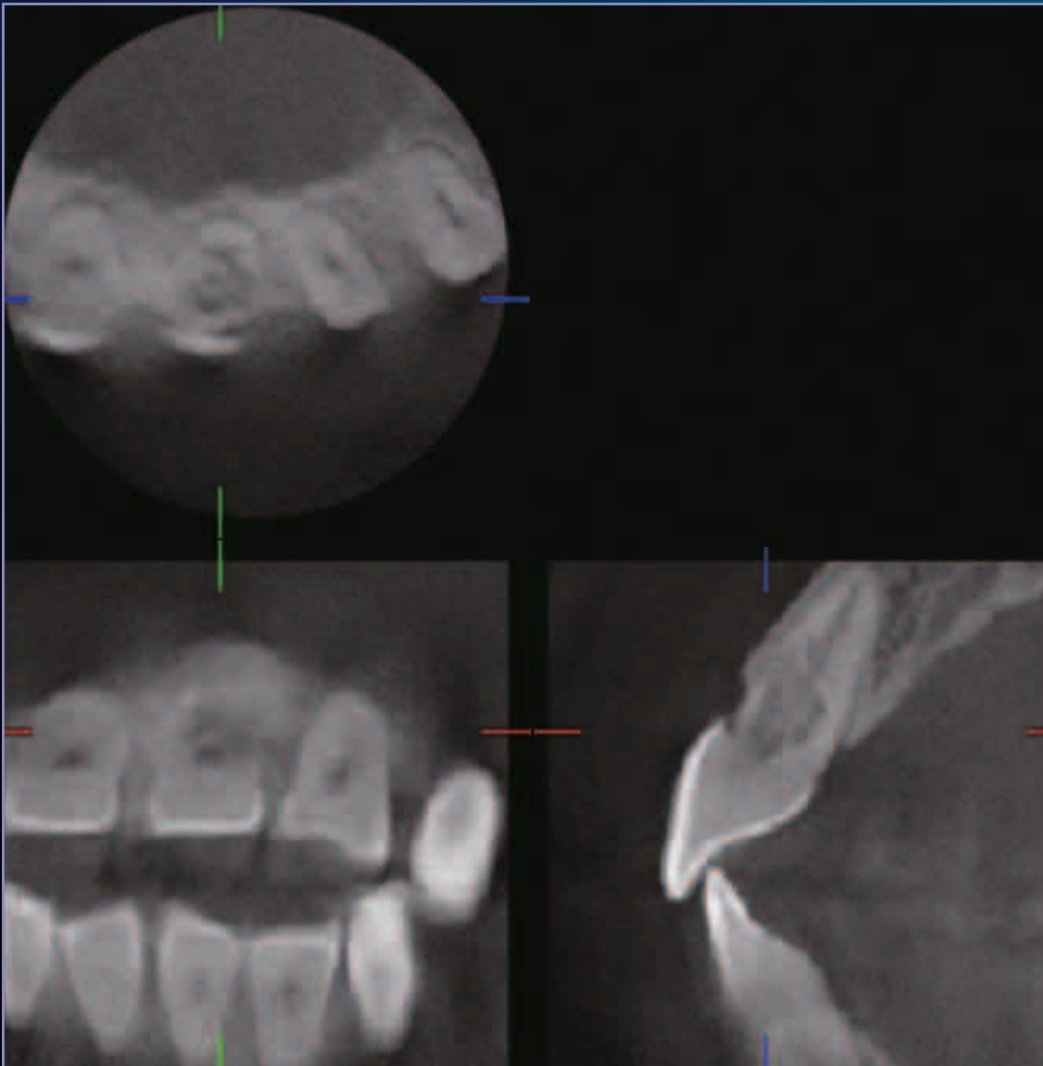
Is the resorption internal or is it external?

How extensive is the damage to the tooth?

What is the prognosis?

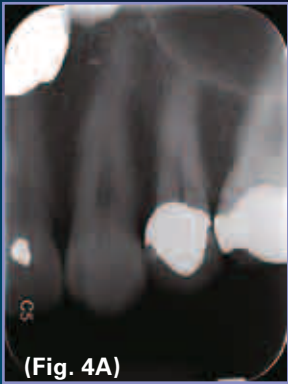The 3D Accuitomo images make it very clear that we are dealing with a cervical resorption.

The cervical (external) resorption extensively invades tooth #9. The process is highly destructive, yet it has not invaded the pre-dentin surrounding the pulp. The 3D images clearly demonstrate a destructive process that makes the prognosis for tooth retention poor.



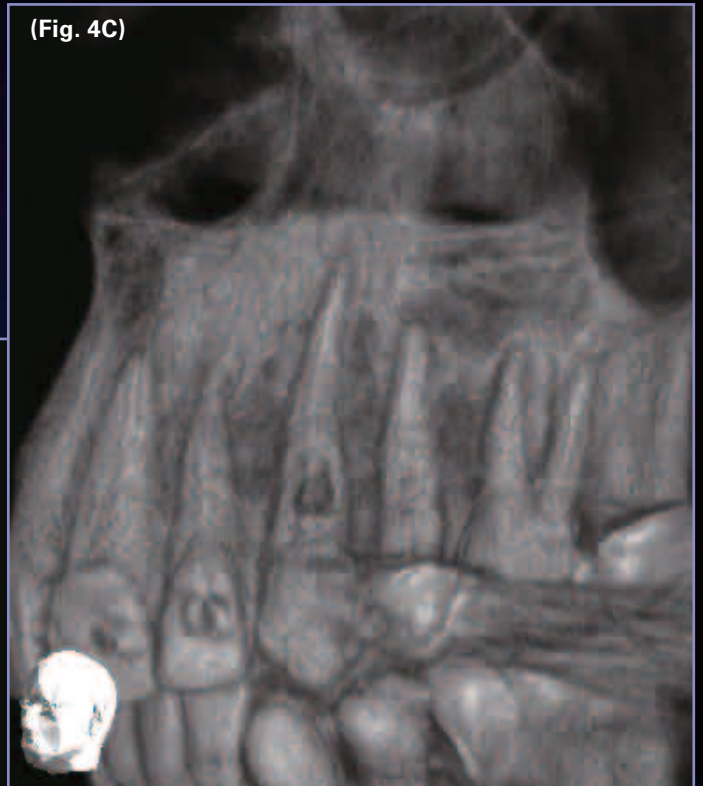
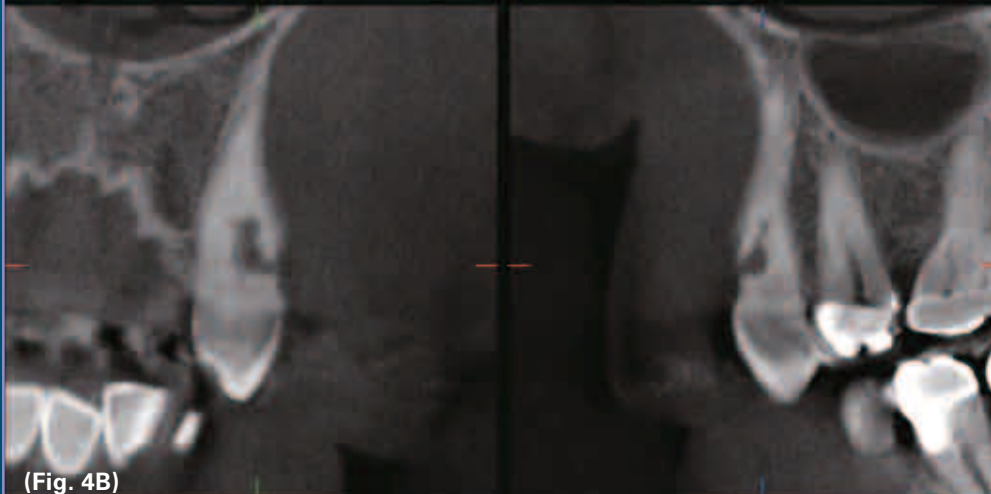
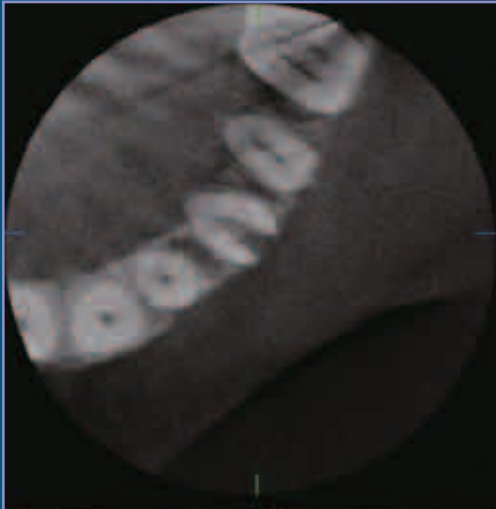
*-The case in this page was provided by Alan H. Gluskin, DDS Professor taken with the 3D Accuitomo.*

## INTERNAL RESORPTION CASE 3



The patient presented with pain to palpation over tooth #11. Vitality testing revealed that the tooth was vital. The conventional pre-operative radiograph showed an unusual appearance of the root canal space just apical to the CEJ (Fig. 4A).

All periradicular bone appeared to be normal. Accuitomo imaging revealed (Figs. 4B & C) a large internal/external resorption defect on the buccal surface of the root just above the osseous crest of bone, dictating extraction. Typically, treatment of this tooth would have been instituted, wasting the patient's time and money when the tooth was hopeless.

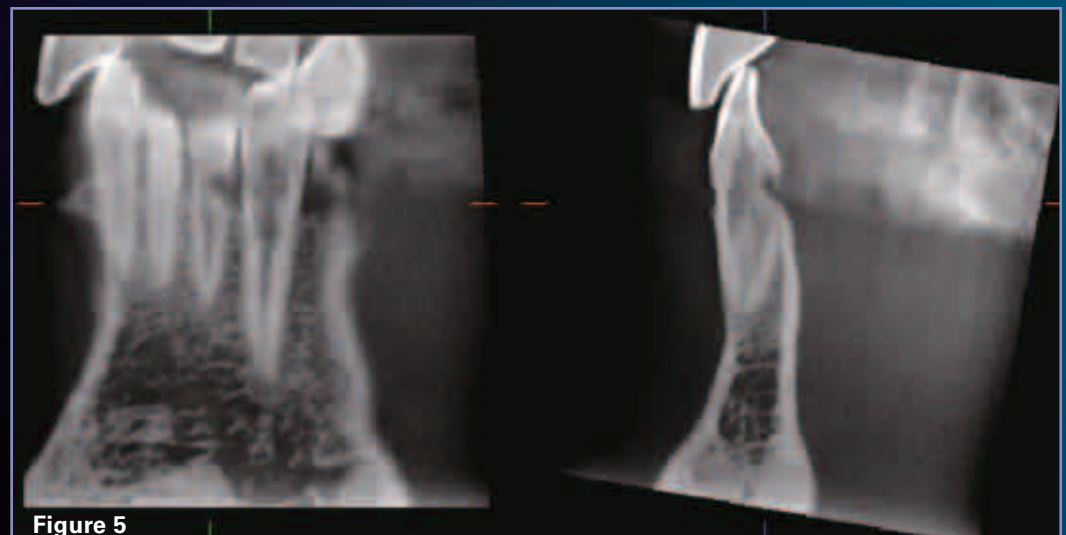


-The case in this page was provided by Dr. L. Stephen Buchanan taken with the 3D Accuitomo.

## INTERNAL RESORPTION CASE 4

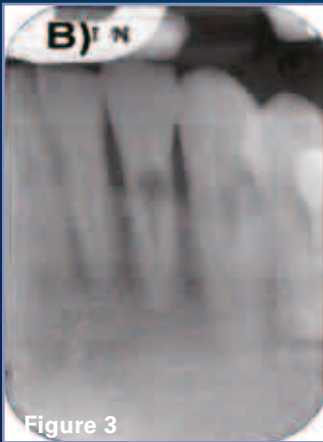

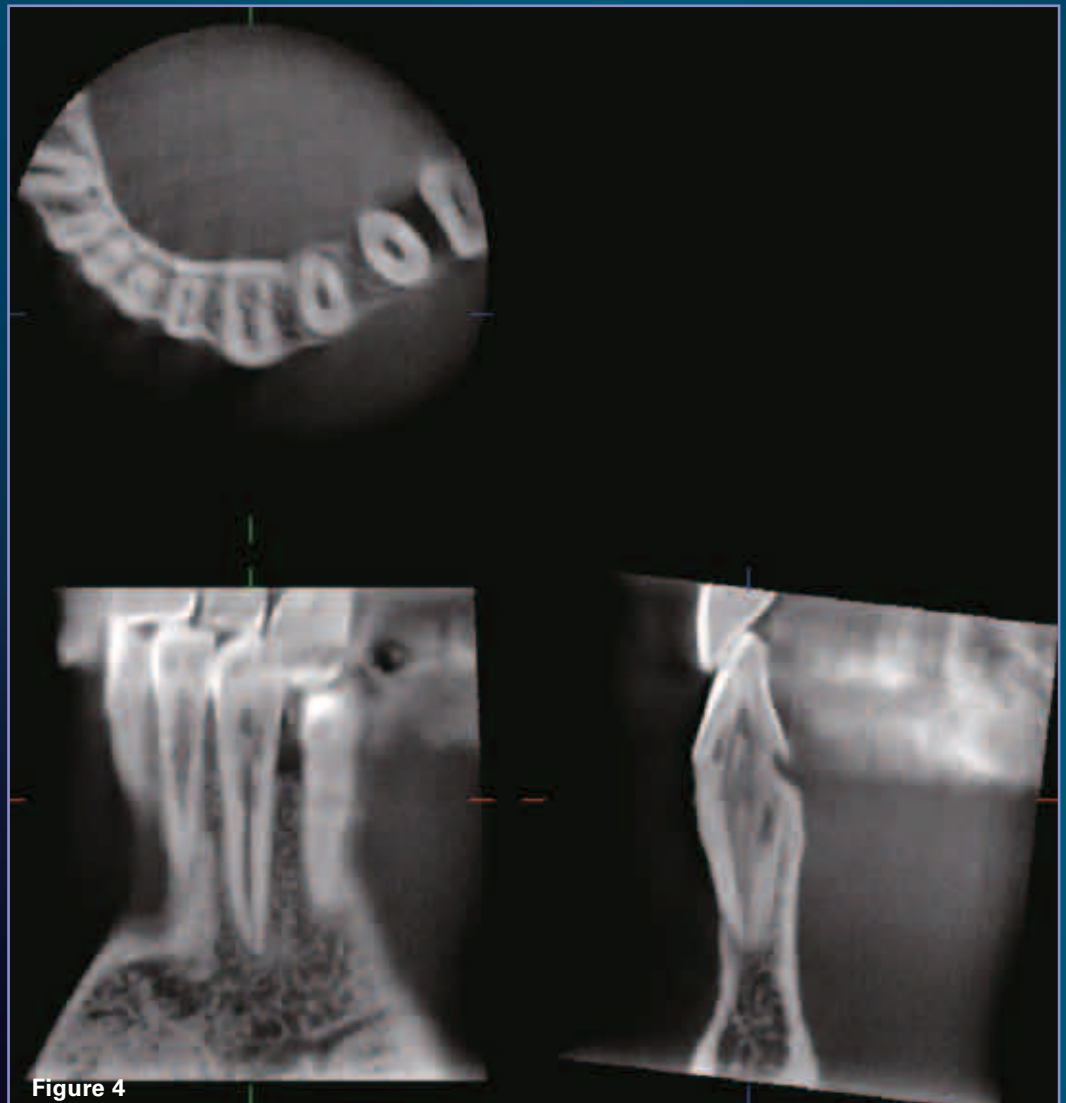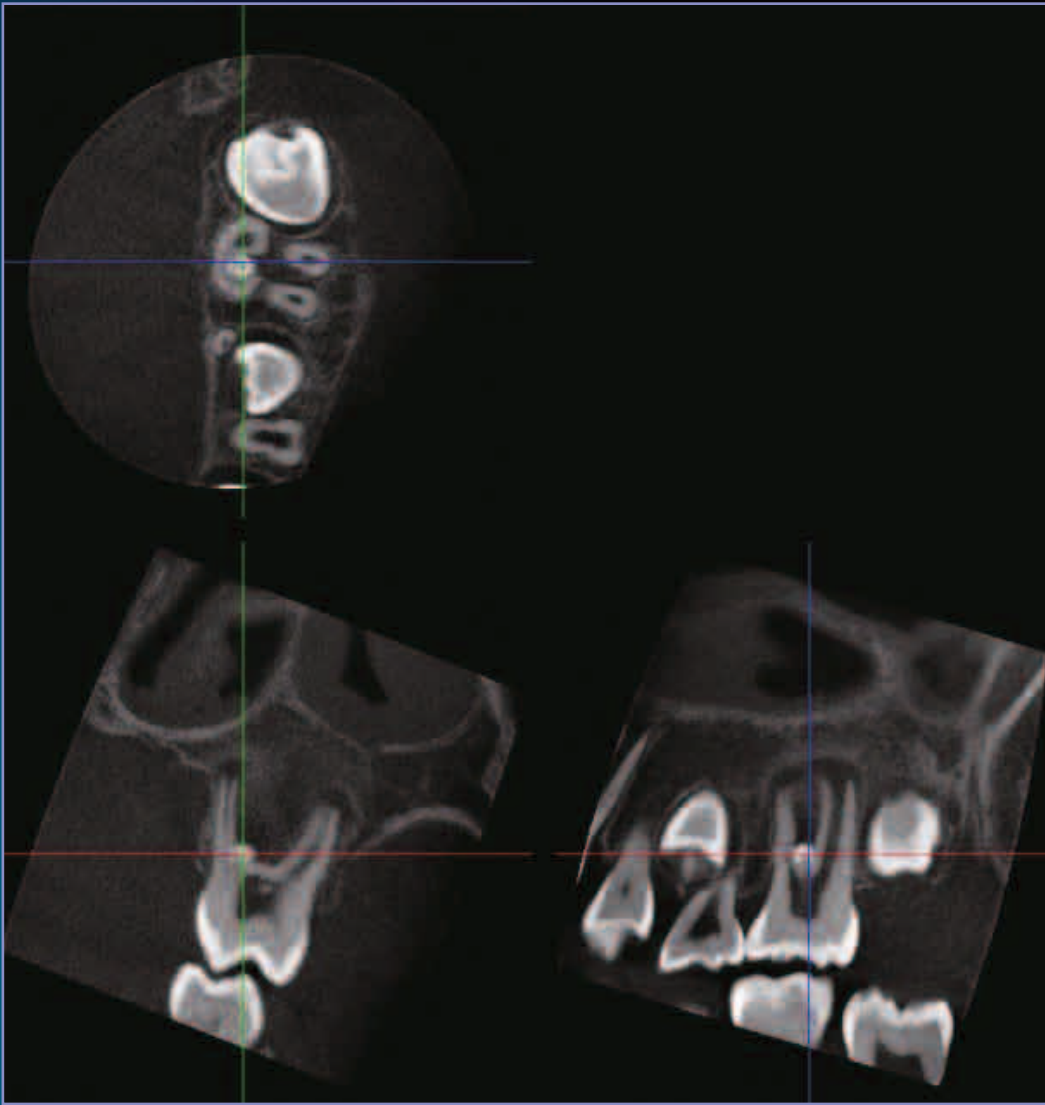Fig. 3 shows the panoramic (Fig. 3A) and periapical (Fig. 3B) radiographs of a 54 year old asymptomatic male patient. These radiographs, taken during a routine dental examination, reveal enlargement of the pulpal cavity of teeth #22 and 23, consistent with internal resorption. However, these radiographs do not offer any information regarding the extent of the resorption and thus do not aid in the treatment planning (i.e. endodontic treatment vs. extraction) of the patient. Clinical examination was unremarkable. An Accutomo scan delineated the extent of internal root resorption in both teeth. Interestingly, in addition to the internal resorption, external resorption at the cervical area of both #22 and #23 was observed. Based on the extent of the internal and presence of external root resorption the teeth were deemed unrestorable.



-The case in this page was provided by Dr. Sotirios Tetradis taken with the 3D Accutomo.

## ENAMEL DROP



This young girl presents with pain localized to the upper left first molar region. The accutomo examination reveals the presence of an enamel pearl in the palatal part of the interradicular area. There are two palatal roots that become fused as they come close to the crown forming a crescent shaped curvature in which the enamel pearl is found. The sagittal image (lower right image) shows the two palatal roots. In the interradicular area, and surrounding the enamel pearl, a lesion is found. In addition, the apical parts of the roots are surrounded by a denser than normal bone indicating an inflammatory reaction.



## J. MORITA MFG. CORP.

Developed and Manufactured by

**J. MORITA Mfg. Corp.**

680 Higashihama Minami-cho, Fushimi-ku, Kyoto,  
612-8533 Japan  
Tel: +81-75-611-2141, Fax: +81-75-622-4595,  
<http://www.jmorita-mfg.com>

Distributed by

**J. MORITA CORPORATION**

33-18, 3-Chome, Tarumi-cho Suita City, Osaka, 564-8650 Japan  
Tel: +81-6-6380-2525, Fax: +81-6-6380-0585,  
<http://www.asia.morita.com> <http://www.oceania.morita.com>

**J. MORITA USA, Inc.**

9 Mason Irvine, CA 92618 U.S.A.  
Tel: +1-949-581-9600, Fax: +1-949-465-1095, <http://www.jmoritausa.com>

**J. MORITA EUROPE GMBH**

Justus-von-Liebig-Strasse 27A, D-63128 Dietzenbach, Germany  
Tel: +49-6074-836-0, Fax: +49-6074-836-299, <http://www.jmoritaueurope.com>

**SIAMDENT CO., LTD.**

444 Olympia Thai Tower, 3rd Floor, Ratchadapisek Road, Samsennok,  
Huay Kwang, Bangkok 10310, Thailand  
Tel: +66-2-512-6049, Fax: +66-2-512-6099, <http://www.siamdent.com>